Case study 32

Implant Placement into a Fresh Extraction Socket with Immediate Loading

Dr. Stuardo Valenzuela Manfredi

AlphaBio TEC
Simplantology

Dr. Stuardo Valenzuela Manfredi

Dr. Stuardo Valenzuela Manfredi holds a degree in Oral Surgery from the Universidad Mayor, Santiago, Chile (2005). In 2011, Dr. Valenzuela completed his specialty in Oromaxillofacial Implantology at the Universidad de Chile (cum laude), and from 2012, he has been a member of the Oral Implantology Society, Chile. Dr. Valenzuela is the Clinical Director of the Alpha-Bio Tec Training Center in Chile, where he teaches introductory courses in surgery and in prosthetics. Dr. Valenzuela manages a private practice in Santiago, Chile, fully dedicated to implantology. During his career, Dr. Valenzuela has participated in numerous rehabilitation and implant surgery courses, as well as been a presenter at industry events worldwide.

ABSTRACT

Immediate implantation and loading simultaneously has a success rate comparable to implants installed under conventional protocols, if the surgical site meets the conditions mentioned herein. This case examines 54 years old man suffering from pain and mobility in teeth 24 and 25. 2 Alpha-Bio Tec. I.C.E. implants were installed immediately following extraction. The case has six months follow up.

INTRODUCTION

Implant dentistry has developed dramatically over the last three decades. The first implants introduced into the market, cylindrical and machine surface, have evolved to become new, sand-blasted and acid etched surface treatments (SLA). These new implants exhibit significant changes in macro design, have various prosthetic platforms and other major enhancements.

Coupled with these implants changes, patients are actively seeking shorter treatment times, improved functionality and aesthetics. As a result, patients are the driving force behind procedure improvement in implant assisted restoration.

Our literature states that following extraction, the socket takes two to three months to heal prior to implantation, and then three to six months to achieve osseointegration prior to loading. (Albrektsson et al. 1981; Brånemark 1983).

Contrary to these findings, a significant breakthrough has been the immediate implantation following tooth extraction (i.e., installation into a fresh socket). This technique reduces the number of surgical procedures required and the total duration of implant-based processes.

Installing implants immediately following extraction is a predictable procedure (Quirynen et al. 2007; Botticelli et al. 2008; Chen & Buser 2009). Success rates vary between 92.7% (Krump and Barnett 1991) and 98% (Gelb 1993). Also grunder and colleagues, did not find significant differences in long-term survival between immediate (92.4 %) and standard (94.7 %) implants (Schwartz-Arad et al. 2000).

In immediate post-extraction implants, the thickness of the buccal plate and the gap between the buccal plate and the implant can affect the aesthetic outcome. (Caneva et al. 2010a, 2010b, 2013; Ferrus et al. 2010; Tomasi et al. 2010).

To reduce resorption of the buccal plate, the recommended implant position is more palato-lingual, resulting in a thicker buccal space, and filling the gap with bone graft material (Araujo & Lindhe 2005).

Larger diameter implants, installed in fresh sockets, increase resorption of the buccal plate. It is therefore recommended to use narrow implants. (Lang et al. 1994, 2004; Wilson et al. 1998; Cornelini et al. 2003; Chen et al. 2007). Such implants may compromise primary stability, which is essential when utilizing immediate loading. In this scenario, implant macro design becomes all the more relevant.

The architecture of the buccal plate is influenced by various factors which should be considered prior to deciding upon immediate implantation, including:

- Reason for extraction
- Adjacent pieces - number and distance
- Alveolus status prior to extraction (presence/thickness of vestibular table, condition of soft tissue)
- Patient´s periodontal biotype
- Socket status following extraction (indemnity of vestibular table)
- Periodontal condition
- Temporary piece - fixed or removable
- Pathologies or defects
- Flap or flapless surgery
- Bone quality

Another significant breakthrough in implant installation is flapless surgery. These surgeries result in less intra-surgical bleeding, shorter operating time, accelerated gum healing time and lower morbidity for the patient.

It is well known that flap elevation can result in major trauma in either hard or soft tissue, lead to bone loss and as a result, impact the aesthetic outcome.

Flapless surgery poses some limitations, including difficulty in visualizing the drilling direction and depth and correcting alterations in peri implant tissue (i.e., little keratinized gum, fenestration of the vestibular table, etc.) Flapless surgery also requires a significant quantity and quality of bone, as well as sufficient keratinized gum.

To avoid complications, flapless surgery should be carefully planned using 3D imaging, such as cone beam computed tomography (CBCT), coupled with stringent surgical guidance. In the hands of an experienced surgeon, flapless surgery is a predictable and highly successful procedure.

In 1977, loading protocols submitted by Brånemark et al, showed remarkable innovation. Including healing times of three to six months. Long unloaded healing was recommended to ensure higher success rates in osseointegration. As such, this protocol was used with cylindrical and machine implants without surface treatment. Subsequent advances in surface treatment have since shortened healing times. The conventional two-stage protocol was recommended for machine surface implants and the first release of surface treated implants. Shorter healing times consistent with SLA surface treatment have since been proven in numerous clinical studies (Cochran et al. 1998, 2002).

Implant Placement into Fresh Extraction Socket with Immediate Loading

Stable bone to implant contact free from micromovement, is essential in achieving osseointegration (Horinchi et al. 2000). Following implant insertion, primary stability is mechanical, whereas during the healing process, secondary stability sets in, and is a combination of mechanical and biological stability (Davies 1996; Berglundh et al. 2003).

Micromovements below 100 microns stimulate osteoblasts, while micro movements above 150 microns may result in fibrointegration (Horinchi et al. 2000).

Immediate rehabilitation within 72 hours may be done with or without functional occlusal load. To reduce micromovement of the implant during healing in single-tooth implants, an immediate, non-functional load is recommended (Schnitman 1993; Aparicio et al. 2003).
Primary stability achieved during implant installation is proportional to its macro design (Salvi et al. 2004), while conical implants exhibit greater primary stability than cylindrical implants (Schulte & Heimke 1976; Gomez-Roman et al. 1997). Self-drilling implants are therefore recommended when implants are installed in fresh sockets following extraction. This type of macro design provides adequate primary stability allowing for immediate implant loading. (Akkocaoglu et al. 2005).

CASE DESCRIPTION

A male, 54 years old patient presented in our clinic without a relevant systemic history. His visit was due to pain and mobility in teeth 24 and 25. Clinical examination showed root cavities and increased mobility in these teeth. A decision was made to extract these teeth and replace them with fix screwed implant assisted prosthesis.

Materials Used

- 2 Alpha-Bio Tec. I.C.E. Ø3.7N L 13mm implants
- HS4 D: Ø4.6mm H: 4mm healing abutment Alpha-Bio Tec.
- Demineralized Cortical Granules * (DFDBA – Demineralized Freeze Dried Bone Allograft) Alpha-Bio Tec.
- Plastic customized abutments (PLAS) as temporary abutments
- Chrome-cobalt base customized abutments as definitive abutment

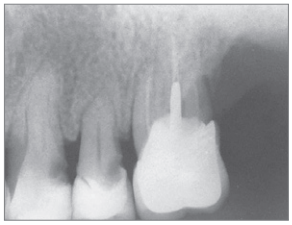

1 Periapical X-ray of teeth 24 and 25 showing root carries

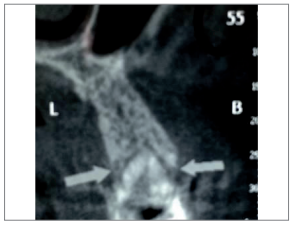

2 Clinical oral image at CT scan

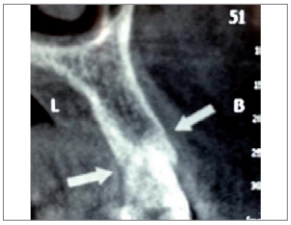

3 CBCT showing bone condition suited to implant insertion in fresh extraction socket

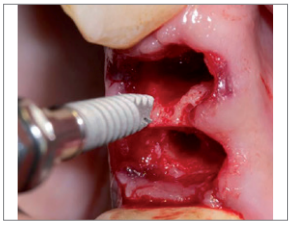

4 When implants are installed in socket after the extraction and we need high primary stability for the Immediate Loading, we have to choose implants with a macrodesign like AlphaBio Tec's I.C.E., with a tapered body both internally and externally, moderate self-drilling capability, and progressive thread design.

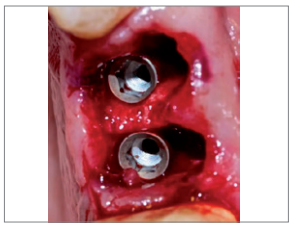

5 Implant position more palatinaly, leaving a >2mm gap to be filled with DFDBA

6 Healing abutments, prior to filling the gap

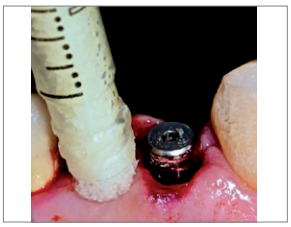

7 GAP filled with DFDBA

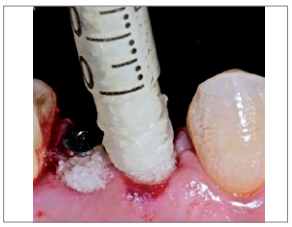

8 Gap filled with DFDBA

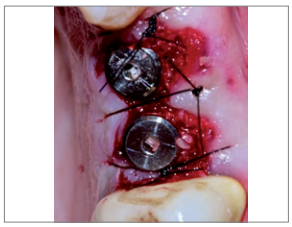

9 5-0 nylon suture

10 Non-functional immediate load on the same day as the surgery, with screwed acrylic temporary piece X-ray

11 X-ray 15 days post procedure

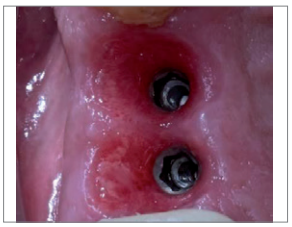

12 Three months post installation of implants, having sculpted soft tissue around temporary pieces; transfers are personalized with an open tray in order to reproduce their shape

13 Impression with putty silicone of the provisional crown for mimic the emergence profile



14 Personalizing transfers with an open tray with acrylic resin

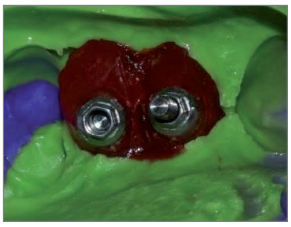

15 Open tray impression with personalized transfers

16 Porcelain-fused to-metal prostheses, screwed onto the artificial gum model

17 Screwed porcelain-fused to-metal prostheses on the day of installation four months post-surgery

18 Sealing the screw access hole with composite

19 Six months post-procedure

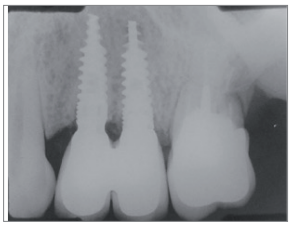

20 1 year post treatment X-ray

Conclusions

Immediate implantation and loading in fresh sockets following extraction has a success rate comparable to that of implants installed under conventional protocols, if the surgical site meets the conditions mentioned herein. Further, the surgical procedure can be performed without flap, reducing morbidity and the amount of surgical procedures patients require, as well as decreasing the length of implant-based treatment. Immediate loading (temporary rehabilitation within 72 hours) is a highly predictable treatment method. This option enables patients to receive a fixed provisional restoration (either screwed or cemented), reducing aesthetic compromise during the procedure. Immediate loading depends on the primary stability achieved on the day of implantation. With a view to achieving strong primary stability, when implants are installed in a fresh sockets following extraction, conical and self-drilling implants are recommended together with an adequate macro-design, such as Alpha-Bio Tec's Implant Classical Esthetics (I.C.E.) implant.

References

Akkocaoglu, M., Uysal, S., Tekdemir, I., Akea, K., et al. Implant design and interosseous stability of immediately placed implants: a human cadaver study. Clinical Oral Implants Research, 2005;16:202-209.

Albrektsson, T., Brånemark , P.I., Hansson, H.A., Lindström J. Osseointegrated titanium implants. Requirements for ensuring a long-lasting, direct bone-to-implant anchorage in man. Acta Orthop Scand, 1981;52(2):155-70.Aparicio, C., Rangert, B., Sennerby, L. Immediate/early loading of dental implants: a report from the Sociedad Española de Implantes World Congress consensus meeting in Barcelona, Spain, 2002. Clin Implant Dent Relat Res., 2003;5(1):57-60.

Berglundh, T., Abrahamsson, I., Lang, N.P., Lindhe, J. De novo alveolar bone formation adjacent to endosseous implants. Clin Oral Implants Res. 2003;14(3):251-62. Botticelli, D., Persson, L.G., Lindhe, J., Berglundh, T. Bone tissue formation adjacent to implants placed in fresh extraction sockets: an experimental study in dogs. Clin Oral Implants Res. 2006;17(4):351-8.

Botticelli, D., Renzi, A., Lindhe, J. and Berglundh, T., Implants in fresh extraction sockets: a prospective 5-year follow-up clinical study. Clinical Oral Implants Research, 2008;19:1226–1232.

Brånemark , P.I., Hansson, B.O., Adell, R., Breine, U., et al. Osseointegrated implants in the treatmnent of the edentulous jaw. Experience from a 10-year period. Scandinavian Journal of Plastic and Reconstructive Surgery Supplementum, 1997; 16:1-132.

Brånemark , P.I., Osseointegration and its experimental background. Journal of Prosthetic Dentistry, 1983;50(3):399-410.

Caneva, M., Salata, L.A., De Souza, S.S., Baffone, G., et al. Influence of implant positioning in extraction sockets on osseointegration: histomorphometric analyses in dogs. Clin Oral Implants Res, 2010a;21(1):43-9. Caneva, M., Salata, L.A., De Souza, S.S., Bressan, E., et al. Hard tissue formation adjacent to implants of various size and configuration immediately placed into extraction sockets: an experimental study in dogs. Clinical Oral Implants Research, 2010b;21: 885–890.

Caneva, M., Botticelli, D., Viganò, P., Morellim,F., et al. Connective tissue grafts in conjunction with implants installed immediately into extraction sockets. An experimental study in dogs. Clin Oral Implants Res. 2013;24(1):50-6.

Chen, S.T., Darby, I.B., Reynolds, E.C. A prospective clinical study of non-submerged immediate implants: clinical outcomes and esthetic results. Clin Oral Implants Res. 2007;18(5):552-62.

Chen, S.T., Buser, D., Clinical and esthetic outcomes of implants placed in postextraction sites. Int J Maxiofac Implants, 2009;24:186-217.

Cochran, D.L., Schenk, R.K., Lussi, A., Higginbottom, F.L., et al. Bone response to unloaded and loaded titanium implants with a sandblasted and acid-etched surface: a histometric study in the canine mandible. J Biomed Mater Res. 1998;40(1):1-11.

Cochran, D.L., Buser, D., ten Bruggenkate, C.M., Weingart, D., et al. The use of reduced healing times on ITI implants with a sandblasted and acid-etched (SLA) surface: early results from clinical trials on ITI SLA implants. Clin Oral Implants Res. 2002;13(2):144-53.

Cornelini, R., Rubini, C., Fioroni, M., Favero, G.A., et al. Transforming growth factor-beta 1 expression in the peri-implant soft tissues of healthy and failing dental implants. J Periodonto. 2003;74(4):446-50.

Davies, J.E. In vitro modeling of the bone/implant interface. Anat Rec. 1996;245(2):426-45.

Favero, G., Lang, N.P., De Santis, E., Gonzalez, G.B., et al. Ridge preservation at implants installed immediately after molar extraction. An experimental study in the dog. Clin. Oral Impl. Res. 2013,255–261.

Ferrus, J., Cecchinato, D., Pjetursson, E.B., Lang, N.P., et al. Factors influencing ridge alterations following immediate implant placement into extraction sockets. Clin Oral Implants Res. 2010;21(1):22-9

Gelb DA. Immediate implant surgery: three-year retrospective evaluation of 50 consecutive cases. Int J Oral Maxillofac Implants. 1993;8:388-399.

Gomez-Roman, G., Schulte, W., d'Hoedt, B., Axman-Krcmar, D. The Frialit-2 implant, Int J Oral Maxillofac Implants; 1997;12 (3): 299-309.

Horinchi, K., Uchida, H., Yamamoto, K., Sugimira, M. Immediate loading of Brånemark system implant following placement in edentulous patients: A clinical report. Int J Oral Maxillofac Implants. 15:824-830.
Krump, J.L., Barnett, B.G., The immediate implant: a treatment alternative. ,Int J Oral Maxillofac Implants. 1991;6(1):19-23.

Lang, N.P., Wetzel, A.C., Stich, H., Caffesse, R.G. Histologic probe penetration in healthy and inflamed peri-implant tissues. Clin Oral Implants Res. 1994;5(4):191-201.

Lang, N.P., Berglundh, T., Heitz-Mayfield, L.J., Pjetursson, B.E., et al. Consensus statements and recommended clinical procedures regarding implant survival and complications. Int J Oral Maxillofac Implants. 2004;19:150-4.

Nkenke, E., Hahn, M., Lell, M., Wiltfang, J., et al. Anatomic site evaluation of the zygomatic bone for dental implant placement. Clinical Oral Implants Research, 2003;14: 72–79.

Quirynen, M., Van Assche, N., Botticelli, D., Berglundh, T.How does the timing of implant placement to extraction affect outcome? Int J Maxiofac Implants, 2007; 22: 202-203.

Romanos, G., Toh, C.G., Siar, C.H., Swaminathan, D., et al. Peri-implant bone reactions to immediately loaded implants. An experimental study in monkeys. J Periodontol, 2001; 72(4): 506-511.

Salvi, G.E., Lang, N.P. Diagnostic parameters for monitoring peri-implant conditions.Int J Oral Maxillofac Implants. 2004;19:116-27.

Schnitman, P.A. Implant dentistry: where are we now? J Am Dent Assoc. 1993;124(4):38-47. Schulte, W., Heimke, G., Das Tubinger Sofort-implantat, Quintessenz, 1976;27(1).

Schwartz-Arad D, Grossman Y, Chaushu G. The clinical effectiveness of implants placed immediately into fresh extraction sites of molar teeth. J Periodontol 2000; 71:839-844.

Tarnow, D.P., Emtiaz, S., Classi, A. Immediate loading of threaded implants at stage 1 surgery in edentulous arches: ten consecutive case reports with 1- to 5-year data. Int J Oral Maxillofac Implants. 1997;12(3):319-24.

Tomasi, C., Sanz, M., Cecchinato, D., Pjetursson, B., et al. Bone dimensional variations at implants placed in fresh extraction sockets: a multilevel multivariate analysis. Clin Oral Implants Res. 2010;21(1):30-6.

Wilson, T.G. Jr, Schenk, R., Buser, D., Cochran, D. Implants placed in immediate extraction sites: a report of histologic and histometric analyses of human biopsies. Int J Oral Maxillofac Implants. 1998;13(3):333-41.

Authorized regulatory representative:

EC REP **MEDES LIMITED**
5 Beaumont Gate, Shenley Hill
Radlett, Herts WD7 7AR. England
T./F. +44.192.3859810

www.alpha-bio.net

995-8031 R1/06.15