



The Use of Alpha-Bio Tec's Narrow NeO Implants with Cone Connection for Restoration of Limited Width Ridges



Dr. Amir Gazmawe

DMD, Specialist in Prosthodontics,
Israel

Dr. Amir Gazmawe graduated from the Hebrew University of Jerusalem, Hadassah School of Dental Medicine in 2001 and completed his post-graduate specialization in prosthodontics also at Hebrew University in 2008. Dr. Gazmawe has extensive experience in prosthodontics using implants and was a clinical instructor at the Dental Implant Center, Hadassah Hospital, Jerusalem. He is currently a consultant in prosthodontics in the Intensive Care Unit, Poriya Medical

Center, Tiberias (Israel), as well as a course instructor in the Hebrew University of Jerusalem, Hadassah School of Dental Medicine. Dr. Gazmawe lectures in Israel and abroad on integrated implant prosthodontics and dental aesthetics. He manages a private implantology and prosthodontics clinic in Ramat Hasharon, Israel.

The Use of Alpha-Bio Tec's Narrow NeO Implants with Cone Connection for Restoration of Limited Width Ridges

Background

Narrow ridges have been treated using two approaches: enhancing bone volume by augmenting the ridge (using one of several different techniques) or by using narrow implants^[1]. In cases of severe ridge resorption, particularly in the esthetic zone, the option of two stage surgery is indicated for optimal results^[2,3]. However, in cases involving mild to moderately resorbed ridges, both the implant placement and the augmentation procedure can be done simultaneously if the implants can be adequately stabilized in the residual bone^[4].

Several parameters are critical in achieving good primary stability for a single stage procedure:

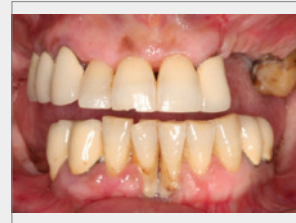
1. Residual ridge volume and dimensions and bone density should be determined by examining the CT scan and the drilling protocol should be modified accordingly^[5].
2. Since the implant position determines the decision whether or not to augment the buccal bone, the implant position, both vertically and horizontally, coupled with esthetic, functional, and occlusal considerations of the final restoration, must be decided upon prior to surgery^[6].
3. The appropriate implant design should be selected for each individual case.

In the following case study, the most suitable implant design was the Alpha-Bio Tec. NeO implant, due to its unique design and properties. The NeO implant can easily be stabilized when there is both limited bone dimension and limited bone density due to its tapered spiral implant design, self-tapping apical portion, and its ability to gently condense the bone as it is seated^[7].

In the minimally invasive approach to surgery, which is used in order to avoid augmentation procedures that can be costly and time-consuming, narrow implants are indicated. Narrow implants are considered safe and predictable for the long term survival of fixed prostheses^[8]. The design of narrow implants can vary and includes one-piece implants, as well as either external or internal connections with a hex or a conical connection. The advantage of internal conical connections has been demonstrated in long term studies, especially with regard to minimal cervical resorption after loading^[9]. This advantage is even more important when placing implants in limited bone width ridges. Obviously, it is easier to achieve the minimum primary stability required for immediate loading and restoration when the implant is fully covered with natural bone^[10].

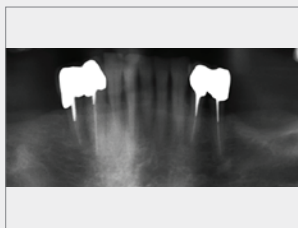
Case Overview

A 54-year old healthy female patient with no known allergies presented with a chief complaint of unstable teeth, missing teeth and inability to chew. (**Figs. 1-3**)

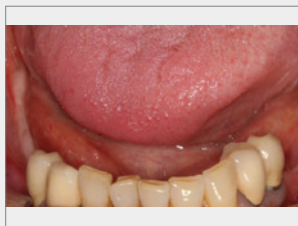


1

Pretreatment status; tooth loss, resorption of ridges and periodontal defects



2 Panoramic X-ray shows atrophic posterior edentulous ridges



3 Posterior laterally atrophic ridges

Dental Background

Loss of posterior teeth due to a history of periodontitis. The patient had a removable partial denture, however, did not use it. The patient requested fixed restorations.

Materials In Use

Ø3.2mmXL13mm NeO implants
 Healing abutments HSD3.4-5-CHC Ø3.4XH5mm
 Esthetic Angled Titanium Abutments ETLAL15-CHC
 Alpha-Bio's GRAFT Natural Bovine Bone
 Alpha-Bio's GRAFT Collagen Membrane

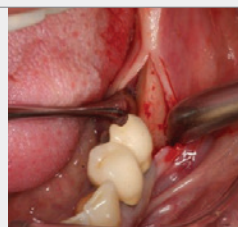
Treatment Plan

Fixed implant supported restorations in the mandible: 3 implants at teeth positions 45, 46, and 47 and 2 implants at positions 36 and 37. (Figs. 4-13) According to the CT scan of these areas, the width of the ridge was 5-6 mm in these specific positions.

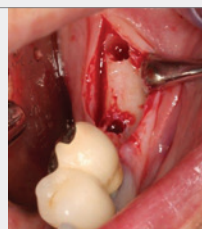The use of standard implant systems would require GBR in order to obtain a minimum of 2 mm of buccal bone. Alternatively, narrow Ø3.2mm NeO implants were selected for implantation, with no augmentation procedure on the left side and one stage augmentation on right side with a minimally invasive approach.

Surgical Procedure

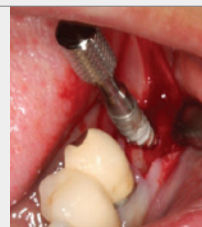A mid-crestal incision distal to the premolar tooth with no releasing flap. Drilling in the relevant molar positions with a pilot drill to the full implant depth and with a 2.8 mm drill through the cortical bone (3-4 mm). Five 3.2 diameter 13 mm length NeO implants were inserted in one stage surgery. (Figs. 4-13)



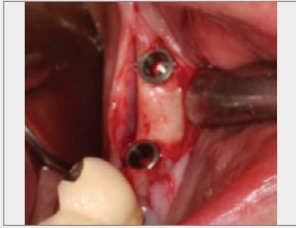
4 Mid-crestal incision shows the narrow ridge



5 Drilling using 2 and 2.8 mm drills

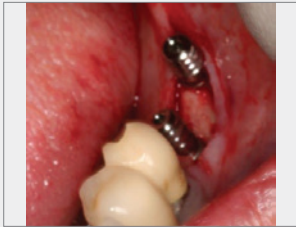

6 Implant placement, first manually and then using a 40N/cm insertion torque



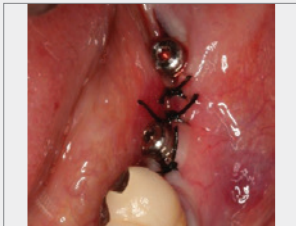7

Implants were inserted at bone level; 2 mm of buccal bone is available



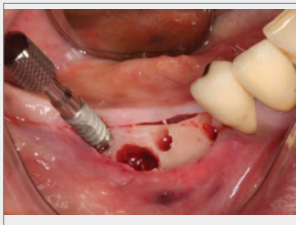
8

Healing caps were connected, platform switching is visible



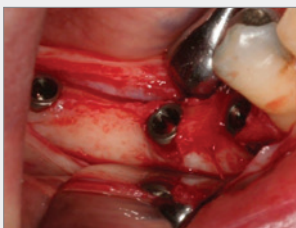9

Suturing



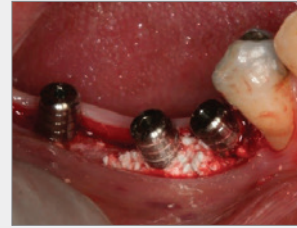10

Right side implant placement



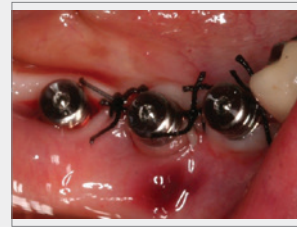11

Bone level positioning, small exposed areas are visible



12

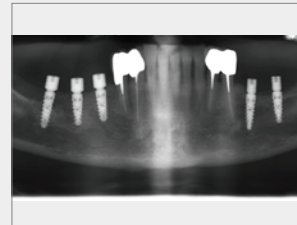
Buccal augmentation procedure using bovine bone substitute and resolvable membrane (Alpha-Bio's GRAFT)



13

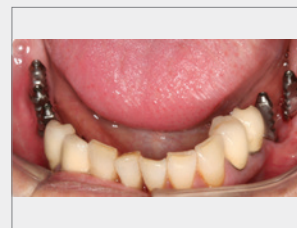
Suturing

Prosthodontics Treatment (Figs. 14-19)



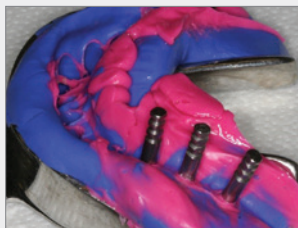14

X-ray at 3 months after surgery shows good integration and no cervical resorption



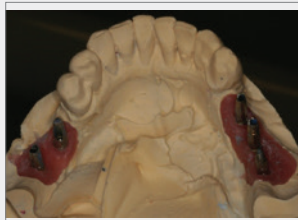15

Impression taken using closed tray transfers for narrow implants



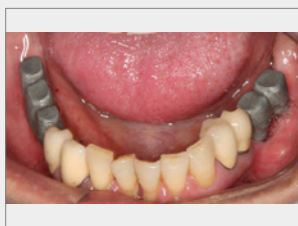
16

Analogs connected to transfers and placed back into the impression



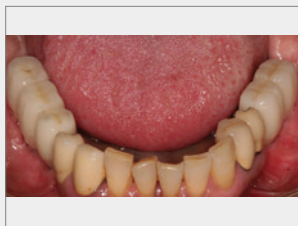
17

Abutment modification and metal casting



18

Metal base of PFM (Porcelain-Fused-to-Metal) crowns is positioned for passive fit



19

Final restoration 4 months after implantation

Conclusion

Narrow implants can be used with good prognoses when placed in natural bone. It is important to choose the appropriate implants. The unique design of NeO implants results in primary stability following the implant procedure. In addition, the use of conical connection helps to avoid resorption of a thin buccal bone plate after implant loading.

References

1. Degidi M, Piattelli A, Carinci F. Clinical Outcome of Narrow Diameter Implants: A Retrospective Study of 510 Implants. *J Periodontol.* 2008; 79:49–54
2. Andersen E, Saxegaard E, Knutsen BM, Haanaes HR. A prospective clinical study evaluating the safety and effectiveness of narrow-diameter threaded implants in the anterior region of the maxilla. *Int J Oral Maxillofac Implants.* 2001; 16:217–24
3. Cordaro L, Torsello F, Mirisola Di Torresanto V, Rossini C. Retrospective evaluation of mandibular incisor replacement with narrow neck implants. *Clin Oral Implants Res.* 2006; 17:730–5
4. Mericske-Stern R, Grutter L, Rosch R, Mericske E. Clinical evaluation and prosthetic complications of single tooth replacements by non-submerged implants. *Clin Oral Implants Res.* 2001; 12:309–18
5. Polizzi G, Fabbro S, Furri M, Herrmann I, Squarzone S. Clinical application of narrow Branemark System implants for single-tooth restorations. *Int J Oral Maxillofac Implants.* 1999; 14:496–503
6. Vigolo P, Givani A. Clinical evaluation of single-tooth mini-implant restorations: a five-year retrospective study. *J Prosthet Dent.* 2000; 84:50–4
7. Zarone F, Sorrentino R, Vaccaro F, Russo S. Prosthetic treatment of maxillary lateral incisor agenesis with osseointegrated implants: A 24-39-month prospective clinical study. *Clin Oral Implants Res.* 2006; 17:94–101
8. Romeo E, Lops D, Amorfini L, Chiapasco M, Ghisolfi M, Vogel G. Clinical and radiographic evaluation of small-diameter (3.3-mm) implants followed for 1-7 years: A longitudinal study. *Clin Oral Implants Res.* 2006; 17:139–48
9. Vigolo P, Givani A, Majzoub Z, Cordioli G. Clinical evaluation of small-diameter implants in single-tooth and multiple-implant restorations: A 7-year retrospective study. *Int J Oral Maxillofac Implants.* 2004; 19:703–9
10. Vigolo P, Givani A. Clinical evaluation of single-tooth mini-implant restorations: A five-year retrospective study. *J Prosthet Dent.* 2000; 84:50–4