14

ENGLISH

SIMULTANEOUS GUIDED BONE REGENERATION AND IMPLANT INSERTION

DR. GADI SCHNEIDER

Professional

AUTHOR:

DR. GADI SCHNEIDER

D.M.D & Specialist in Periodontics,
Alpha-Bio Tec Research and Academic Consultant.

Dr. Schneider received his D.M.D. certificate at the Hebrew University Hadassah Dental School in Jerusalem, in 2000.

Following this, he did his post-graduate studies in Periodontology at the same school, and has been a specialist in Periodontology since 2004. He received his European Federation Certificate of Periodontology in 2004 and has worked as an instructor and lecturer in Jerusalem Hebrew University, Hadassah Dental School.

As the Research and Education consultant and lecturer at Alpha-Bio Tec's Educational Center, Dr. Schneider provides seminars and courses in Implantology and implant surgery to his colleagues in the field. Dr. Schneider also holds a private practice which specializes in Periodontics and Implantology.

Sophisticated

SIMULTANEOUS GUIDED BONE REGENERATION AND IMPLANT INSERTION

AUTHOR:

DR. GADI SCHNEIDER

D.M.D & SPECIALIST

IN PERIODONTICS

DEFINITIONS

REGENERATION:

The reconstruction of damaged or destroyed tissue resulting in the reconstructed tissue being identical to the original tissue in composition, morphology and function.

REPAIR:

The reconstruction of damaged or destroyed tissue, where the reconstructed tissue is consequently different from the original tissue (scar or Long JE).

BASIS: BONE SUBSTITUTES – FAMILIES, TYPES AND PROPERTIES

PROPERTIES:

OSTEOGENIC	OSTEOINDUCTIVE	OSTEOCONDUCTIVE
• Active stimulation • Contains Osteogenic cells • Bone formation in the bone tissue itself	• Active stimulation • Bone formation in other tissues due to the inductive ability of parental cells to become osteogenic and form bone	• Passive stimulation • Ability to act as a matrix to which the bone cells attach, grow and multiply, thus encouraging bone formation

FAMILIES AND PROPERTIES:

AUTOGENIC SOURCE (FROM THE PATIENT)	ALLOGENIC SOURCE (FROM ANOTHER PERSON)	XENOGENIC SOURCE (FROM AN ANIMAL)	ALLOPLASTIC SOURCE (SYNTHETIC)
Pelvic, chin, mandible bone	Organ donation, DFDBA, FDBA	Bovine, porcine, equine	CAP, CAS and other polymers HA, TCP, CAS, GALSS

PROPERTIES:

Osteogenic Osteoconductive Osteoinductive	Osteoconductive Osteoinductive (only DFDBA)	Osteoconductive	Osteoconductive

ADVANTAGES AND DISADVANTAGES:

• Medical theoretic gold standard • Fast rate resorption • Additional surgical site • High morbidity • High proficiency • Limited availability	**DFDBA** • Recommended for small defects only, or for medium and large defects, sinus lifts combined with other materials • Fast rate resorption (2-4 months) **FDBA** • Medium rate resorption (6-15 months) • For all defects, sinus lifts	• High dimensional stability • slow rate resorption • Market leader • Highly conductive • Well-researched • Effective in all procedures	• Medium rate resorption • Effective in sinus lifts • Effective in bone regeneration combined with other materials

BACKGROUND

Guided bone regeneration is based on guided tissue regeneration in the field of periodontics. In 1976 it was suggested that the way a lesion heals depends on the type of cells populating that lesion (Melcher 76).

Subsequently, a series of papers found that PDL cells are the type of cells responsible for guided tissue regeneration, and that the prevention of epithelial and connective tissues from reaching the healing area by means of a physical barrier (membrane) allows the PDL cells to populate the root of the tooth and bring about the formation of cementum, PDL and bone (regeneration).

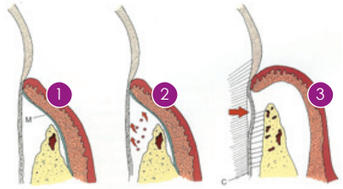

Membrane placement | Penetration of PDL and bone cells | Bone, Cementum and PDL

It was also determined that when the membrane was crushed and only a small space was left between it and the tooth, only cementum and a small amount of bone were formed. However, when the membrane maintained more substantial volume, a large amount of new bone was formed (Gottlow 84)

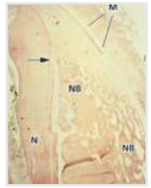

The conclusion drawn from the series of papers was that it is possible to extrapolate from the principle of successful guided tissue regeneration to bone regeneration alone, by creating a space and a physical barrier that permits only bone-forming cells to penetrate the space and fill it with bone. This theory is the current basis for guided bone regeneration. Pursuant to this theory, several clinical studies were conducted in which bilateral bone defects were created and a membrane was placed on one side but not on the other. The research results unequivocally demonstrate that new bone was generated on the side on which a membrane was placed, whereas only soft tissue was generated on the other side (Dahlin 88, 89), Kastapoulus & Karring 94, Karring 94).

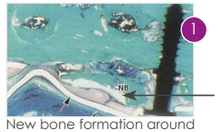

New bone formation around the titanium screw



Soft tissue formation around the titanium screw

THE BONE FORMATION PROCESS

Histological evidence shows that new bone formation under the membrane takes place following the same process, and in the same phases, as native bone formation in the alveolus after a tooth extraction, namely:

1. Blood clot formation protected by the membrane
2. Granular tissue formation
3. Woven bone formation
4. Lamellar bone formation
5. Bone remodeling

The entire process takes from 4 to 6 months (Schnek 94).

Woven bone

Lamellar bone

CASE 1. Guided bone regeneration around an SPI – 23 implant by means of bovine bone and collagen membrane

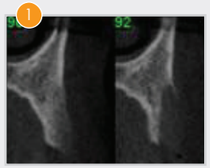

CT before

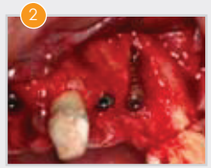

Buccal bone loss

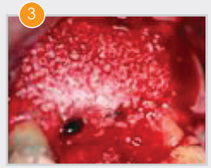

Bone placement

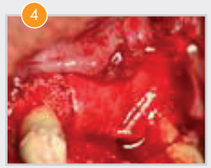

Membrane placement

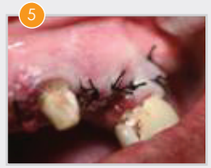

Primary closure

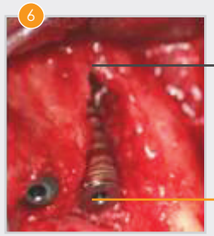

Before

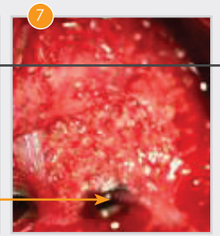

After 6 months

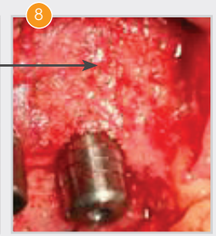

After 6 months

CLINICAL STUDIES

Clinical studies comparing implants inserted into regenerated bone vs. implants inserted into native bone show the following:

- Both share the same clinical, radiographic and histomorphometric characteristics
- There is a similar degree of bone - implant contact (BIC)
- There is a similar degree of crestal bone resorption (Fritz & Reddy, 2001; Zitman, 2001; Hammerle, 2003)

SIMULTANEOUS GUIDED BONE REGENERATION AND IMPLANT INSERTION

In order to perform bone regeneration simultaneously with implant insertion, three principles should be observed:

- Primary stability of the implant
- Ideal rehabilitative position of the implant
- Appropriate size and shape of the defect enabling the achievement of the previous two conditions

PRINCIPLES OF GUIDED BONE REGENERATION DEMONSTRATED WITH IMPLANT 22

In a series of case presentations and studies, Buser (1995) proposed a surgical protocol comprised of 7 principles aimed at achieving predictable results in guided bone regeneration:

1. Primary closure of soft tissue to prevent membrane exposure, using an appropriate incision and flap elevation technique.

Use of vertical incisions

2. Placement of the implant in ideal rehabilitative position.

3. Bone preparation - decortication aimed at enabling osteoprogenitor cells from the bone marrow to reach the defect. A number of papers published in the recent years showed that decortication is not necessary in order to achieve predictable results.

Decortication

4. Creation and maintenance of a sub-membranal space, aimed at preventing a prolapse of the membrane into the defect, through the use of bone substitutes or other means of membrane support.

Buccal bone placement

5. Close adaptation and fixation of the membrane by means of suturing, or fixation to the bone with pins, aimed at:
   - Preventing the penetration of soft tissue cells into the defect area
   - Preventing the displacement of the membrane in order to avoid soft tissue formation underneath

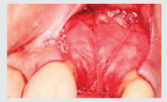

Fixation with absorbable sutures

Shaping the membrane for full adaptation

6. Achieving primary closure by means of releasing incisions and suturing.

Suturing

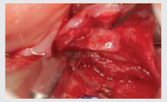

Releasing incisions

7. Following a healing period of 6 to 7 months to allow maximum healing and bone-fill.

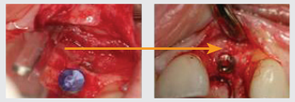

SUMMARY

- Guided bone replacement regeneration is an efficient and predictable procedure
- More than 90% success in over two years follow-up on 656 implants (Nevins M, Int. J. Perio Restor Dent 98, Lorenzoni, COIR 99, Dahlin, COIR 91)
- 90-100% of bone filling under the membrane after a waiting period of 6-8 months (Long N.P.: COIR 94:5, 92-97)
- More and more evidence in the professional literature shows that absorbable membranes perform as well as inabsorbable membranes in lateral guide bone regeneration (Hammerlee, C.H.F.: Periodontology 2000:Vol 33,2003:36-53
- There is no difference between regenerative bone and native bone regarding BIC and the success rate of implants (Zitman NU, JOMI 2001:16:355-366)

CASE 2. Guided bone regeneration around an SPI 22 – 23 – 24 implant utilizing bovine bone and collagen membrane

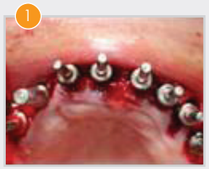

1 Positioning

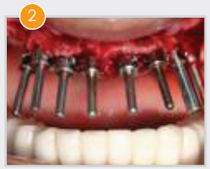

2 Positioning

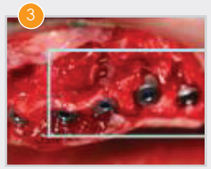

3 Buccal bone loss

4 Bone placement

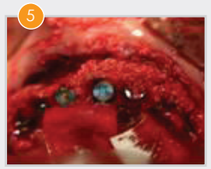

5 Bone placement

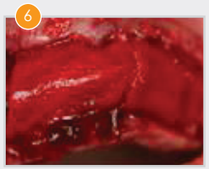

6 Membrane placement

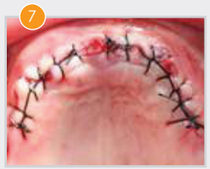

7 Primary closure

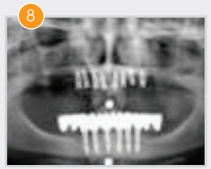

8 Panoramic radiography

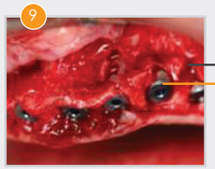

9 Before

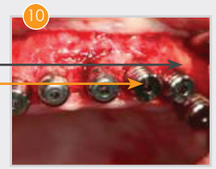

10 After 6 months

CASE 3. Guided bone regeneration around DFI 22 – 23 – 24 implants utilizing bovine bone and collagen membrane

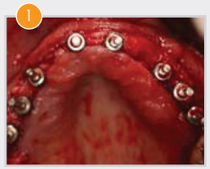

1 Positioning

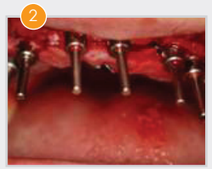

2 Positioning

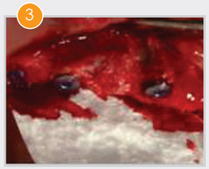

3 Buccal bone loss

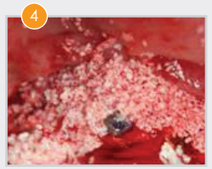

4 Bone placement

5 Membrane placement

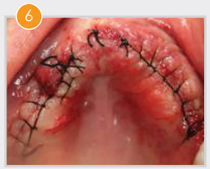

6 Primary closure



7 Before

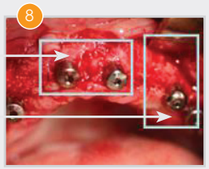

8 After 6 months

AlphaBio's GRAFT

www.alpha-bio.net

Alpha-Bio Tec's products are cleared for marketing in the USA and are CE-marked in accordance with the Council Directive 93/42/EEC and Amendment 2007/47/EC.

Alpha-Bio Tec complies with ISO 13485:2003 and the Canadian Medical Devices Conformity Assessment System (CMDCAS).

Alpha-Bio Tec Ltd.

7 Hatnufa St. P.O.B. 3936, Kiryat Arye,
Petach Tikva 49510, Israel
T. +972.3.9291000 | F. +972.3.9235055
sales@alpha-bio.net

International

T. +972.3.9291055 | F. +972.3.9291010
export@alpha-bio.net

EC REP **MEDES LIMITED**

5 Beaumont Gate, Shenley Hill,
Radlett, Herts WD7 7AR. England
T/F. +44.192.3859810