

Case study 25

Implantology Solutions for Atrophic Maxilla Using Short Implants

Dr. Ariel Labanca Mitre

Oral Implantology Specialist
Prosthodontics Specialist

Introduction

Given the current boom of implantology, we are starting to witness a growing number of complex cases where due to the patient's condition, severe alveolar resorption is present, so that inserting an implant can often be quite challenging, requiring additional surgery to increase bone mass. This usually occurs in the posterior maxillary and mandibular regions, where there is a risk of damaging the lower dental nerve or perforating the maxillary sinus floor during implant insertion, increasing surgical morbidity and exacerbating post-operative complications. In addition, posterior areas entail greater difficulty in implant insertion (difficult access, limited visibility, reduced space, poor bone quality and heavier occlusal loads).

One predictable alternative for compensating the lack of bone height is implementing surgical bone enhancement techniques, such as maxillary sinus lift, guided bone regeneration, bone distraction, etc., which increase post-surgical morbidity, total cost and length of treatment. As a result, patients tend to be reluctant to this option (Kotsovilis et al., 2009; Anitua et al., 2008; Morand & Irinakis, 2007).

Another alternative is the use of short implants. These, however, have traditionally been accused of lower survival rates as compared to implants of conventional length. It was believed that longer implants offered more clinical advantages, owing to a better crown-root ratio, a larger implant area, and thus a greater area for osseointegration.

Current studies have shown that the clinical success rates that can be achieved with short implants are the same as those offered by their traditional longer counterparts, and that their use is a predictable therapeutic alternative both in the short, mid and long term (Fugazzotto, 2008; Maló et al., 2007).

Let us define the term "short implant." Some authors have defined short implants as those that do not exceed 7 mm in length. A short implant is one that is between four and seven millimeters long (Arlin, 2006).

Advantages for implantologists:

- Simple, traditional technique
- No need for guided bone regeneration surgery
- Safe osseointegration

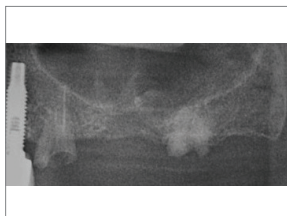Advantages for patients:

- Only one surgery
- 90-day recovery window
- Lower cost

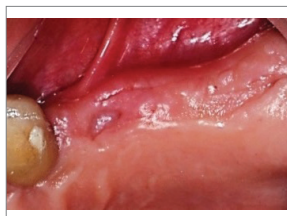Several clinical trials have demonstrated that short implants are comparable in predictability to conventional, long implants, and that maximum bone stress is virtually independent from implant length. Implant diameter is more important than implant length. As far as biomechanics is concerned, reducing lateral occlusal forces on implant-supported prostheses as much as possible and evenly distributing these forces by inserting splinted implants play a significant role in reducing stress on short implants (Anitua & Orive, 2010).

Case 1

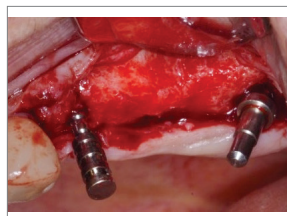
Severe bone atrophy of the right portion of the upper maxilla, with two root remnants. Three implants were inserted avoiding entrance to the maxillary sinus: an immediate 3.3 x 11.5 SPI implant was introduced in position 24, a 5 x 6 ATID implant was inserted in position 25, and a 3.3 x 10 SPI irradiated implant was placed in position 26, seeking to attain anchorage in the maxillary tuberosity area:




1 Presurgical panoramic X-ray revealing a pneumatized maxillary sinus and root remnants with no prior pathologies



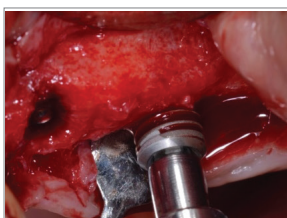2 Presurgical clinical view of the area to be implanted



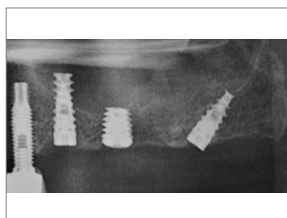
3 Pin insertion and implant distribution avoiding the maxillary sinus floor



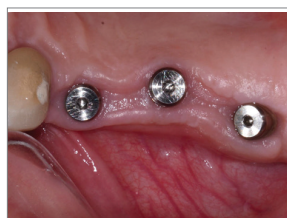4 ATID 5x6 mm implant



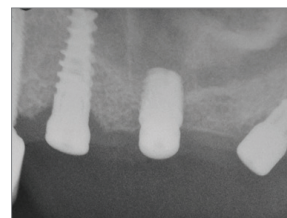
5 Short implant insertion in position 2.5



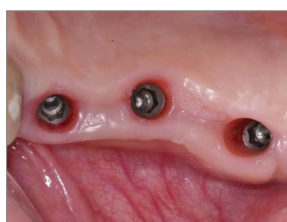6 Post-op panoramic X-Ray, three months after surgery



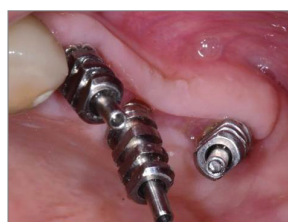7 Second surgery: healing cap placement



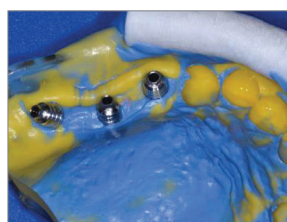
8 Post-second surgery X-ray



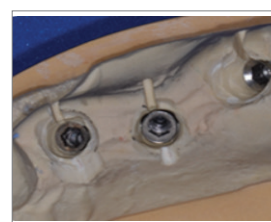
9 Healing cap removal and soft tissue health



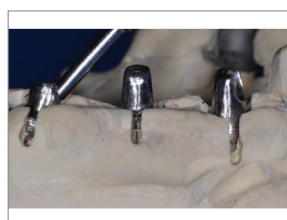
10 Open-tray transfer insertion



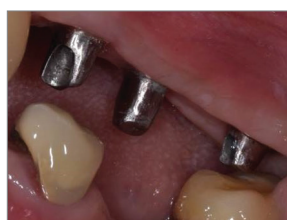11 Transfer impression using an exact copy of the tissue



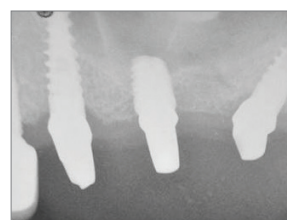
12 Working cast, study of the prosthetic area and casting of the customized abutments



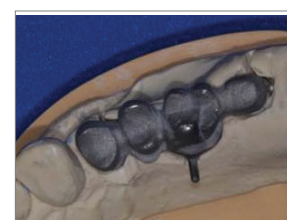13 Working cast, study of the prosthetic area and casting of the customized abutments



14 Insufficient prosthetic space to the antagonist

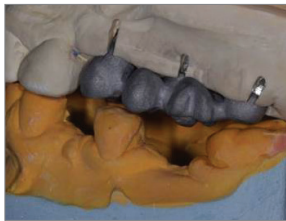

15 X-ray of the cast abutments

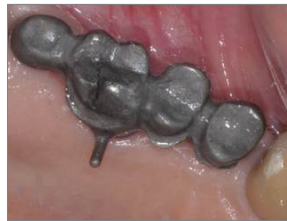

16 Splinted metal structure

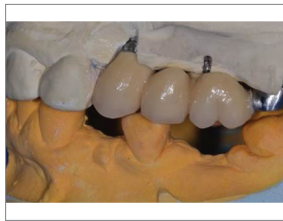Implantology Solutions for Atrophic Maxilla Using Short Implants



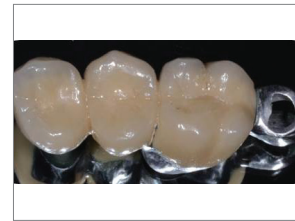17 Room left for occlusion in position 27



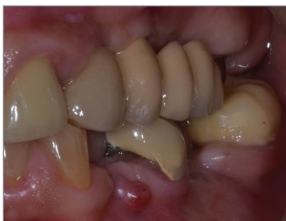18 Testing the structure inside the mouth



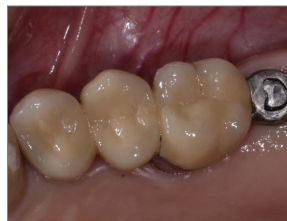19 Testing the porcelain in the assembly



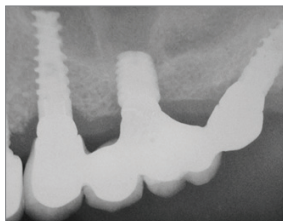
20 Finished splint and free space in position 27



21 Occlusion and disocclusion control



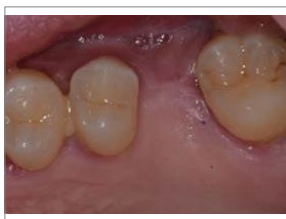22 Splint insertion



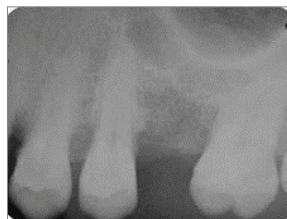23 X-ray of prosthesis adaptation

Case 2

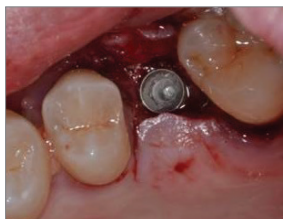Bone resorption resulting from maxillary sinus pneumatization in tooth position 16. A 5x 6 mm ATID implant was inserted in a low density bone avoiding entrance to the maxillary sinus. After a four-month osseointegration process, prosthetic rehabilitation was attained by inserting a TLA 1 abutment and a cement-retained metal-ceramic crown.



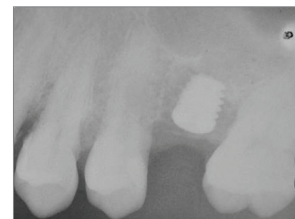1 Pre-op photograph and X-ray of position 16



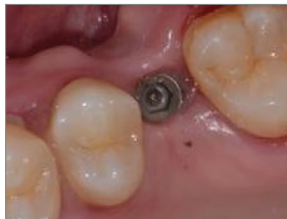2 Pre-op photograph and X-ray of position 16



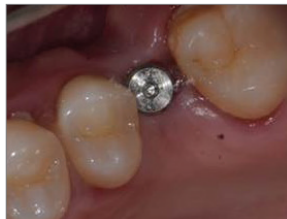3 Insertion of the 5x6 mm ATID implant



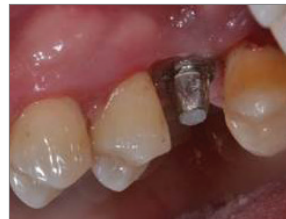4 Post-op X-ray



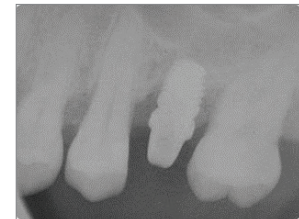
17 Second surgery after four months



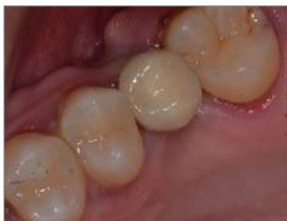18 Healing cap



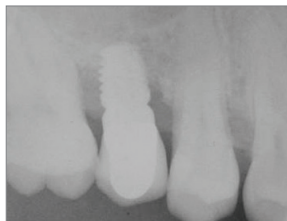19 Carving and torque at 35 N/cm of the TLA 1 straight abutment



20 Abutment control X-ray



21 Metal-ceramic crown placement



22 Prosthetic adaptation control X-ray

Conclusions

Treated surface implants add versatility to the practice of dental implantology. The frequent use of short implants (of 5 or 6 mm in length) on low-density trabecular bones – as is the case with the maxillary tuberosity – delivers results that are comparable to their cylindrical, threaded counterparts. Advantages of short implants include a low-morbidity surgical technique, rapid bone healing, the potential for being used in unfavorable crown-root ratio situations, and a minimal loss of bone crest during function.

In a recent study of 262 short implants with a 53-month follow-up, Tawill et al noticed that an unfavorable crown-implant ratio was not a risk factor for implant failure, as long as force orientation, load distribution and parafunctional habits were properly controlled.

In a review of the literature, it was observed that most cases of short implant failure were mostly due to the surgeon's learning curve and implant placement in low-density bone. Provided the bone bed is duly prepared and treated surface implants are used, expert surgeons can obtain results that are comparable to those delivered by conventional implants. It has been suggested that splinted implants, restoration using a canine occlusion guide and the insertion of implants that increase the bone-implant contact area play a significant role in enhancing implant survival.

Bibliographia

Anitua, E. & Orive, G. Short implants in maxillae and mandibles: a retrospective study with 1 to 8 years of follow-up. *J. Periodontol.*, 81(6):819-26, 2010.

Arlin, M. L. Short dental implants as a treatment option: results from an observational study in a single private practice. *Int. J. Oral Maxillofac. Implants*, 21(5):769-76, 2006.

das Neves, F. D.; Fones, D.; Bernardes, S. R.; do Prado, C. J. & Neto, A. J. Short implants--an analysis of longitudinal studies. *Int. J. Oral Maxillofac. Implants*, 21(1):86-93, 2006.

Fugazzotto, P. A. Shorter implants in clinical practice: rationale and treatment results. *Int. J. Oral Maxillofac. Implants*, 23(3):487-96, 2008.


Maló, P.; de Araújo Nobre, M. & Rangert, B. Short implants placed one-stage in maxillae and mandibles: a retrospective clinical study with 1 to 9 years of follow-up. *Clin. Implant Dent. Relat. Res.*, 9(1):15-21, 2007.

Anitua, E.; Orive, G.; Aguirre, J. J. & Andía, I. Five-year clinical evaluation of short dental implants placed in posterior areas: a retrospective study. *J. Periodontol.*, 79(1):42-8, 2008.

Kotsovilis, S.; Fourmoussis, I.; Karoussis, I. K. & Bamia, C. A systematic review and meta-analysis on the effect of implant length on the survival of rough-surface dental implants. *J. Periodontol.*, 80(11):1700-18, 2009.

Rokni S, Todescan R, Wtason P, Pharoah M, Adeghembo A, Deporter D. An assessment of crown to implant ratios with short sintered porous surfaced implants supporting prosthesis in partially edentulous patients. *Int J Oral Maxillofac Implants* 2005;20:69-76.

Tawil G, Aboujaoude N, Younan R. Influence of prosthetic parameters on the survival and complication rates of short implants. *Int J Oral Maxillofac Implants* 2006;21:275-82.



◉ ◻ ◼ ◽ Smart Implanology Solution



MEDES LIMITED

5 Beaumont Gate, Shenley Hill
Radlett, Herts WD7 7AR. England
T./F. +44.192.3859810

www.alpha-bio.net