

Special reprint from

Volume 25 • Number 2 • 2010

JOMI

The International Journal of
ORAL & MAXILLOFACIAL IMPLANTS

Steven E. Eckert
Editor-in-Chief

**The Efficacy of Full-Arch Immediately Restored
Implant-Supported Reconstructions in
Extraction and Healed Sites:
A 36-Month Retrospective Evaluation**

Zvi Artzi, DMD/Jerry Kohen, DMD/Guy Carmeli, DMD/
Benny Karmon, DMD/Ariel Lor, DMD/Zeev Ormianer, DMD



OFFICIAL JOURNAL OF THE ACADEMY OF OSSEOINTEGRATION

The Efficacy of Full-Arch Immediately Restored Implant-Supported Reconstructions in Extraction and Healed Sites: A 36-Month Retrospective Evaluation

Zvi Artzi, DMD¹/Jerry Kohen, DMD²/Guy Carmeli, DMD³/
Benny Karmon, DMD⁴/Ariel Lor, DMD⁵/Zeev Ormianer, DMD⁶

Purpose: Implants placed in fresh extraction sites and healed sites were restored simultaneously by cross-arch provisional fixed prostheses. Clinical and radiographic parameters were recorded for up to 36 months. **Materials and Methods:** Treatment with a full-arch implant prosthesis, either screw-retained or cemented, was assigned to 54 patients. A total of 676 implants were placed in either immediate extraction sites ($n = 367$) or in healed alveoli ($n = 309$), followed by placement of a one-piece provisional prosthesis. The definitive restoration was placed 3 to 6 months after implant placement. Clinical parameters were recorded and digital radiographs obtained at 6, 18, and 36 months. The chi-square test, t test, and analysis of variance with repeated measures were used for statistical analysis of the outcomes. **Results:** Osseointegration failed in 21 (3.1%) implants; 13 of these (62%) had been placed immediately after extraction. All occurred within 2 months of the surgical healing phase. Short (8-mm) and narrow (3.3-mm) implant configurations were significantly ($P < .05$) associated with failure. At 6, 18, and 36 months, average crestal bone resorption was 0.18 mm, 0.55 mm, and 0.79 mm for implants placed in fresh extraction sites and 0.31 mm, 0.78 mm, and 1.1 mm for implants placed in healed alveoli, respectively. These differences were statistically significant ($P < .05$ between sites at all examined periods). Crestal bone resorption also correlated to sites with simultaneous bone augmentation and implant placement. **Conclusions:** Implants placed and restored immediately in a cross-arch mode, whether in extraction sites or in healed alveoli, can be clinically successful and maintainable. INT J ORAL MAXILLOFAC IMPLANTS 2010;25:329–335

Key words: extraction sites, follow-up, fresh sockets, immediate loading, implant prosthesis, implant success rate

Immediate loading/function of a cross-arch splinted implant-supported fixed prosthesis has become an acceptable approach backed by evidence.^{1–12}

Mechanical loading has shown that inducing controlled amounts of strain could lead to excitation of osteocytes.¹³

Bone cells can sense mechanical loading. This could be related to the fluid flow in the lacunar-canalicular porosity, resulting in an elicited biochemical response.¹⁴ In an in vitro experiment,¹⁵ the use of a strain amplification model resulted in excitation of osteocytes. Since osteoblasts approach the implant surface in close contact,¹³ similar strain would be a significant influence on the osseointegration process.

Others¹⁶ have examined a steady flow shear stress in bone and have reported a significant increase in thymidine (an indicator of proliferation) and alkaline phosphatase activity for osteoblast differentiation. It is understood that a correlation exists between strain magnitude as applied by mechanical loading and its influence on the fate of cells in bone.¹⁷ Consequently, mechanical loading and its biologic factors would

¹Associate Professor, Director of Postgraduate Periodontics, Department of Periodontology, The Maurice and Gabriela Goldschleger School of Dental Medicine, Tel Aviv University, Tel Aviv, Israel.

²Private Practice, Holon, Israel.

³Associate Professor, Department of Periodontology, The Maurice and Gabriela Goldschleger School of Dental Medicine, Tel Aviv University, Tel Aviv, Israel.

⁴Private Practice, Petach-Tikva, Israel.

⁵Private Practice, Tel Aviv, Israel.

⁶Clinical Instructor, Department of Oral Rehabilitation, The Maurice and Gabriela Goldschleger School of Dental Medicine, Tel Aviv University, Tel Aviv, Israel.

Correspondence to: Prof Zvi Artzi, Department of Periodontology, School of Dental Medicine, Tel Aviv University, Ramat Aviv, Tel Aviv 69978 Israel. Email: zviartzi@post.tau.ac.il

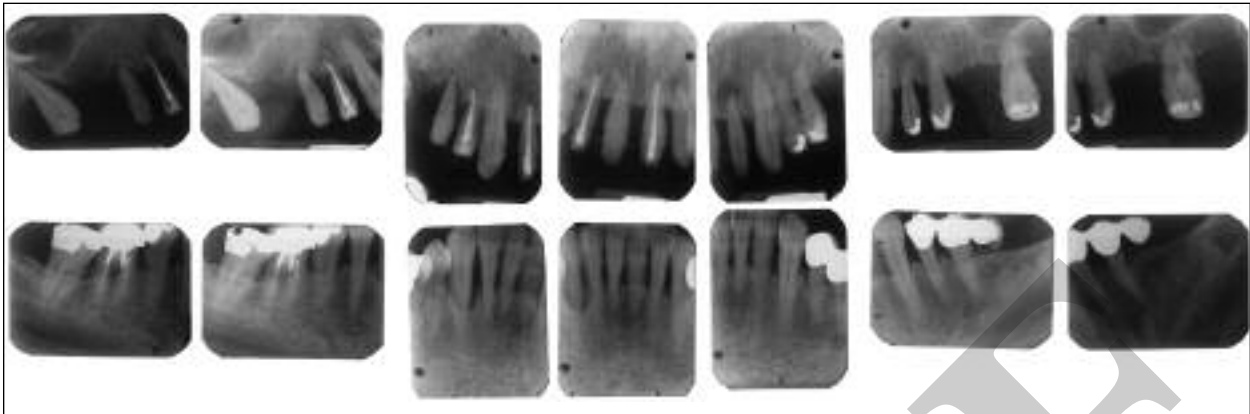


Fig 1 Preoperative full-mouth periapical radiographs revealed severe periodontal damage of the natural dentition.

contribute to well-organized bone,¹⁸ an increase in bone-implant contact,¹⁹ and even an increase in its compact thickness,²⁰ thus resulting in enhanced osseointegration.

Predictable clinical treatment depends on surgical and prosthetic factors. Primarily, the establishment of implant primary stability is mandatory^{10,11} and should not be compromised, particularly during the implant-abutment connection phase. Subsequently, the prefabricated rigid splinted provisional prosthetic framework should be adjusted to achieve optimal occlusion by group function with the opposite arch.

Implant placement immediately postextraction is also a reliable, predictable, and successful procedure.^{21–23} While both techniques are well documented, comparable data regarding placement of immediately loaded implants in extraction sites versus implants placed and loaded in healed edentulous sites are still inadequate, despite recent reports.^{24–26} Therefore, the aim of this retrospective study was to compare the outcome of immediately loaded implants that were placed either in fresh extraction sites or in healed edentulous sites with 6, 18, and 36 months of follow-up.

MATERIALS AND METHODS

Fifty-four patients were scheduled for full-arch implant prosthetic mandibular/maxillary reconstruction between 2001 and 2005. Once treatment started, no patients dropped out. In 24 patients, the procedure was repeated on the opposite arch at a later stage for reasons of morbidity and occlusal equilibration. Thus, full cross-arch prosthetic reconstructions were placed in 78 arches.

The treatment protocol was identical for all patients and for both jaws during the surgical and healing phases and was thoroughly explained. Patients signed an informed consent document. The ethics committee of Tel Aviv University approved the study.

Periodontal status was evaluated by periodontal parameters. Plaque and bleeding indices, probing depth, and tooth mobility were recorded.

Any asymptomatic residual/remaining teeth were extracted on the day of implant placement. However, this only occurred after implants had first been placed in healed edentulous areas.

Any emergency care and/or treatment of any persistent uncomfortable conditions was carried out before initiation of the sequential treatment plan. Study casts and diagnostic wax-ups were created and full-mouth and panoramic radiography (Fig 1) and computed tomography were performed. Implant site locations were determined according to the treatment plan to provide an optimal full-arch fixed implant-supported prosthesis.

At the presurgical appointment, impressions were made; these were used to fabricate provisional restorations that would be placed immediately post-surgery. A surgical guide was prepared by an imprint of the diagnostic wax-up, which was converted to a working plaster model.

All patients were treated under local anesthesia using buccal and lingual infiltration of 1% lidocaine and 1:100,000 epinephrine. A continuous midcrestal incision with an intrasulcular incision around the remaining dentition was made using a Bard Parker No. 15C blade to raise a full mucoperiosteal flap. The prefabricated acrylic resin surgical guide was then stabilized onto the remaining natural dentition (before they were extracted).

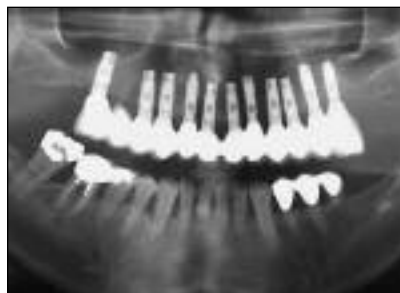

Fig 2 Panoramic view of the reconstructed maxilla after 3 years in function.

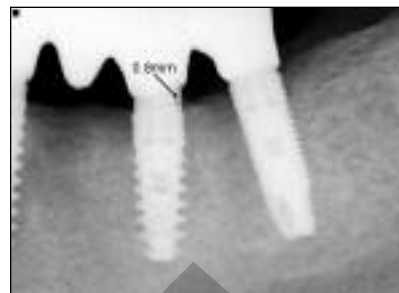


Fig 3 Crestal bone level recorded on digital radiographs mesially and distally at the implant neck.

Implants (DFI, ITO, and SPI internal-hex implants; Alpha-Bio Tec) were placed first in the healed edentulous sites. Most of the implants were of a close-threaded, rough-surfaced, root form configuration (DFI, $n = 515$), and the remaining implants featured greater spaces between threads and were either straight (ITO, $n = 20$) or of a spiral conical shape (SPI, $n = 141$). The latter type of implants were placed primarily in bone types 3 and 4. The implant site was prepared and implants placed at the planned healed (edentulous) sites. The guide was then removed, followed by connection of an implant provisional abutments. Subsequently, all multirooted teeth were separated and all remaining teeth/roots were extracted using root elevators and periostomes. Next, the surgical guide was adjusted to accommodate the new implant provisional prosthetic superstructure. At this stage, implants were placed in the immediate extraction sites according to the treatment plan, followed by connection of additional implant provisional abutments to the newly placed implants in the fresh socket sites. The implant neck was positioned at the level of the osseous crest or the marginal socket walls. Before the provisional abutments were placed, implant primary stability was verified by a torque wrench of 25 Ncm at both fresh extraction and healed sites.

Cervical bone augmentation using a biomaterial bone substitute (Bio-Oss, Geistlich Pharma) overlaid by a bilayer resorbable collagen membrane (BioGide, Geistlich Pharma) was applied in 111 sites, where there was a wide gap of more than 2 mm and/or a denuded implant thread caused by crestal bone deficiency. Additionally, sinus elevation was performed in 15 sites to host 30 implants where the residual posterior maxillary bone height was less than 10 mm. In all, 676 implants (367 in fresh extraction sites and 309 in healed edentulous ridge sites) were placed; 374

implants were inserted in the mandible and 302 were placed in the maxilla.

Soft tissue closure was obtained around the implant superstructures. A provisional cemented wire-reinforced acrylic resin prosthesis ($n = 69$) was applied when the placed implants were parallel and in relative proximity to each other, approximately 3 mm apart. Otherwise, a provisional screw-retained denture ($n = 9$) was relined and inserted using prefabricated plastic sleeves around the emerging implant abutments. All implants were loaded, whether they had been placed in immediate extraction sites or in edentulous sites. During this stage, occlusal adjustments were performed carefully.

Postoperative antibiotics consisted of amoxicillin (500 mg three times daily for 7 days; Moxypen, Teva Pharmaceuticals) and an analgesic agent as needed (200 to 400 mg; Etodolac, Etopan, Taro). Patients were scheduled for weekly recall and were instructed in gentle but meticulous oral hygiene. Probing depths and plaque and bleeding indices were monitored regularly. However, neither the acrylic resin nor the screw-retained provisional prostheses were disconnected during the healing phase in order not to jeopardize the osseointegration/osseous remodeling formation. At 3 to 6 months postoperatively, depending on the complexity of the restorative phase and patient availability, the definitive prosthetic restoration in either arch was placed and retained with cement or screws.

Comprehensive clinical and radiographic (Fig 2) evaluations were performed at 6, 18, and 36 months after implant placement. At each examination, the crestal bone level in relation to the implant neck was measured mesially and distally and recorded digitally (Fig 3) by orthoradial periapical radiographs (with the aid of a gutta-percha point at the occlusal plane and taped to the film for reproducibility).

Table 1 Implant Failure Data

Data	No. of implants	No. of failures	% failure
Type of site			
Fresh socket	367	13	3.5
Healed	309	8	2.6
Total	676	21	3.1
Implant length (mm)			
8	20	4*	20.0
10	118	6	5.1
11.5	67	0	0
13	324	10	3.1
16	147	1	0.7
Implant diameter (mm)			
3.3	68	6**	8.8
3.7	356	9	2.5
4.2	171	3	1.8
5.0	81	3	3.7

* $P < .001$; ** $P < .05$.

Chi-square tests were used to analyze the success and failure rates with regard to the different categorical parameters, analysis of variance with repeated measures was used to analyze the longitudinal data, and the *t* test was employed for continuous variables. Statistical significance was considered at $P < .05$. All findings were analyzed statistically in regard to patient ($n = 54$) and implant ($n = 676$) data.

RESULTS

Patient Data

There were 21 implant failures (in seven women and three men, 18.5%); of these, 12 failed in three patients. These arches were reconstructed with a screw-retained denture. On average, patients with implant failures had a higher number of placed implants. However, this failure tendency was not significant ($P = .08$).

The study included 31 women (57.4%) and 23 men (42.6%) ranging in age from 34 to 81 (average, 57.5 ± 9.2 years). Six patients reported controlled diabetes (three noninsulin-dependent and three insulin-dependent). Three patients reported osteoporosis, with long-term use of alendronate sodium (10 mg/day). None of these patients experienced implant failures. Twenty-one patients (38.9%) reported smoking on a regular basis (more than 15 cigarettes per day). At least one implant failure occurred in six of the smoking patients (28.6%), compared to four (12.1%) nonsmokers.

Because of the small number of patients, no statistically significant differences and/or any conclusions could be drawn from any of the patient data figures, regarding gender, age, medical condition, or habits (smoking, etc).

Implant Data

Table 1 lists the results regarding implants that were placed and failed. Within the first 2 months, 21 (3.1%) of the 676 implants failed and were removed: 13 (3.5%) implants had been placed in immediate extraction sites and 8 (2.6%) had been placed in healed edentulous sites. The difference was not statistically significant. These failures were disclosed at the time of the reevaluation, upon the first retrieval of the provisional prosthesis. Eventually, these implants failed to integrate.

In some cases, implant length or diameter appeared to affect survival (Table 1). Twenty percent of 8-mm-long implants failed; whereas for 10-mm, 11.5-mm, 13-mm, and 16-mm implants, failure rates were 5.1%, 0%, 3.1%, and 0.7%, respectively. The number of failures related to implant length was significant only at 8 mm ($P < .001$).

With regard to implant diameter, 8.8% of 3.3-mm-diameter implants failed, in contrast with 2.5%, 1.8%, and 3.7% failure rates for 3.7-mm, 4.2-mm, and 5.0-mm implants, respectively (Table 1). A statistically significant relationship was found between implant diameter and failure only for the 3.3-mm implants ($P = .035$).

In the anterior ($n = 145$) and posterior ($n = 157$) maxilla (302 implants; 32 arches), six implants failed (2.1% and 1.9%, respectively; 98% survival rate). In the anterior ($n = 174$) and posterior ($n = 200$) mandible (374 implants; 46 arches), 15 implants failed (4.0% for both; 96% survival rate). Despite these failures, because of the implants' distribution, these patients eventually received their restorations, but with fewer implants.

Cervical bone augmentation was performed around 111 implants by guided bone regeneration principles using biomaterial particles protected by a resorbable membrane. Because five implants (4.5%) did not achieve osseointegration, they were removed. Apical augmentation by sinus floor membrane elevation was performed in 15 patients combined with placement of 30 implants. All achieved successful osseointegration.

Crestal bone levels around the implant neck were recorded at each follow-up evaluation and are listed in Table 2. At 6 months, there was an average crestal bone resorption (CBR) of 0.18 mm (range, 0 to 3 mm; SD, 0.5 mm) at fresh extraction sites compared to 0.31 mm (range, 0 to 3 mm; SD, 0.5 mm) at healed edentulous sites; this represented a statistically significant

difference ($P = .002$). At 18 months, mean CBR was 0.55 mm (range, 0 to 3 mm; SD, 0.9 mm) at fresh socket sites and 0.78 mm (range, 0 to 3 mm; SD, 1.08 mm) at healed edentulous sites. This difference was also statistically significant ($P = .03$). At 36 months, mean CBR was 0.79 mm (range, 0 to 2 mm; SD, 1.1 mm) at fresh socket sites and 1.1 mm (range, 0 to 2 mm; SD, 1.3 mm) at healed edentulous sites—again representing a statistically significant difference ($P < .05$).

The progression of CBR over time was significantly greater ($P < .001$) at the healed edentulous sites compared to fresh extraction sites. There was an interaction between time and type of implant site ($P = .004$): the course of CBR over time was slower at fresh extraction sites than at healed edentulous sites.

CBR at the 111 cervical augmented sites was compared to CBR at the nonaugmented sites (Table 2). At 6 months, the average CBR was 0.37 mm (range, 0 to 3 mm; SD, 0.63 mm) at augmented sites, compared to 0.22 mm (range, 0 to 3 mm; SD, 0.49 mm) at nonaugmented sites (statistically significant difference; $P = .019$); at 18 months, mean CBR was 0.87 mm (range, 0 to 2.5 mm; SD, 1.1 mm) at augmented sites compared to 0.62 mm (range, 0 to 3 mm; SD, 0.96 mm) for nonaugmented sites ($P < .05$); and after 36 months in function, mean CBR was 1.1 mm (range, 0 to 2 mm; SD, 1.4 mm) at augmented sites compared to 0.89 mm (range, 0 to 2 mm; SD, 1.1 mm), for nonaugmented sites ($P < .05$). The cumulative CBR over time at augmented sites also showed significantly greater resorption compared to nonaugmented sites ($P = .017$).

DISCUSSION

An immediate functional implant in a cross-arch splinted restorative mode has proven to be a reliable and successful implant reconstructive approach.^{4-6,12} A high survival rate has also been shown regarding immediate postextraction placement of implants.²⁷ Meta-analysis of immediate versus early versus delayed loading¹⁰ shows no significant difference. Primary implant stability appears to play a principal role in predictable success.^{9-11,28,29}

A systematic search of the current literature²³ as related to this procedure showed a survival rate above 95% in 34 prospective/retrospective studies. The addition of controlled loading did not affect the results.^{3,18,24,25} Furthermore, when other factors such as a noninflamed environment are excluded, loading contributes to greater direct bone-implant contact.¹⁹ Whether implants were placed in an extraction site or in a healed alveolar ridge, immediate function did not compromise their prognosis.

Table 2 Crestal Bone Levels

Site	Crestal bone resorption (mm)		
	6 mo	18 mo	36 mo
Extraction site*	0.18 ± 0.5 SD	0.55 ± 0.9	0.79 ± 1.07
Edentulous site*	0.31 ± 0.5	0.78 ± 1.08	1.1 ± 1.26
Cervical augmented site†	0.37 ± 0.63	0.87 ± 1.1	1.1 ± 1.4
Nonaugmented site†	0.22 ± 0.49	0.62 ± 0.96	0.89 ± 1.1

* , † = Progression over time $P < .001$.
Vertical lines = $P < .05$.

Without interfering with the traditional Brånemark principles used to achieve osseointegration,³⁰ loading of implants, done with meticulously balanced cross-arch splinting, could be as predictable and successful^{1,2,6,9} as the two-stage approach. Additionally, immediately loaded implants as part of the full cross-arch splinting could be equally successful whether placed in immediate extraction sites or in healed sites.^{24-26,31}

An earlier report on the immediate placement/immediate loading protocol showed a 5-year cumulative survival rate of 80%.⁵ Only four implants per patient were loaded immediately in that study. Apparently, this combined surgical/prosthetic modality is more appropriately employed with a larger number of implants. In the current report, the average number of implants per arch was 8.6.

Davarpanah et al³² reported a relatively high failure rate in the surgical phase of early loaded implants in fresh extraction (9%) and healed sites (20%). However, the loading phase, which indicated screwed in/out implant superstructure components, occurred 3 to 4 days after implant placement. This could jeopardize the critical wound healing fibrin organization that benefits early osseointegration.

As shown in the present data, implant length and/or diameter could influence the successful outcome of this technique.³³ Despite the low number of narrow and short implants placed, there were 10 failures (8 mm in length: $n = 20$, with 4 failures; 3.3 mm in diameter: $n = 68$, with 6 failures), which were statistically significant with regard to the number placed. It is noteworthy that 4 of the 6 failed 3.3-mm-diameter implants and 2 of the 4 failed 8-mm-long implants were retrieved from extraction sites. Recent data have shown that diameter and/or length are determinant factors.³⁴ Short and/or narrow implants are not recommended for use in a fresh socket. However, the small number of these implants used in the present

study did not allow for statistical conclusions. In a critical review of the immediate loading approach, implant design is suggested as one of the principal factors in ensuring a successful outcome.⁴

In the present study, CBR accumulated with time, which has also been reported after 6 and 12 months.^{35,36} In both extraction and healed sites, the rate of resorption slowed over time, as evidenced by the smaller differences in CBR between the second and third evaluations. In a recent report of a similar surgical/prosthetic approach in the maxilla, CBR was 1.6 mm at 8 months, 2 mm at 20 months, and 2.1 mm at 32 months.⁸ Although extraction and healed sites were comparable in success, there was a significant difference in relation to the CBR around the implant neck over time between the two sites.

It is noteworthy that, for implants placed in the fresh extraction sites, CBR was significantly less than for the healed sites, as measured after 6, 18, and 36 months. This was unexpected to a degree, based on some short-term histologic findings in dogs.^{37,38} However, the present results were based on long-term clinical observations that were based on radiographic interpretation of cases that involved immediate cross-arch loading. Histologic studies^{18–20} show that this factor might enhance the quality and degree of surrounding osseous tissue around the implant neck and surface. The nature of physiologic healing in a fresh socket, the osteogenesis cascades on one side, and the involvement of immediate loading may contribute to greater stability of osseous healing around the implant neck.

In a 3-year prospective study of immediately functional full-arch implant prostheses in the mandible,⁹ CBR was 0.8 mm at 1 year, 1 mm at 2 years, and 1.3 mm at 3 years. These figures resemble the results observed for the healed extraction sites in the present study but represent greater resorption than was seen for the current immediate extraction sites. A digital radiographic examination of 150 implants after 18 months²⁴ placed in extraction sites and loaded immediately strengthened and confirmed these results. A possible explanation could be related to the nature of healing and continual remodeling of the organized clotted untouched crestal area of the extraction site around the immediately placed implant cervical neck, versus the one after the implant site preparation by the mechanically rotated motorized surgical burs at the crestal bone at the healed site. An extraction site, as an appropriate implant housing site, is comparable to a healed osseous table and could be advantageous for healing around an implant body with an osteoconductive titanium surface. However, this was not the case when cervical augmented and nonaugmented sites

were compared. In the present study, there was significantly greater CBR at augmented sites around the implant neck compared to nonaugmented sites at 6, 18, and 36 months. Nevertheless, both types of site showed minor resorption that did not exceed 1 mm CBR after 3 years.

CONCLUSION

Clinical parameters proved equable whether implants were placed immediately postextraction or in a healed alveolar ridge. Cross-arch immediate loading of implants placed in extraction and/or healed edentulous sites were predictable and maintainable, as evaluated periodically after 3 years' observation.

ACKNOWLEDGMENTS

The authors would like to thank Mrs Ilana Gelerenter for the statistical analysis and Ms Rita Lazar for editorial assistance.

REFERENCES

1. Tarnow DP, Emtiaz S, Classi A. Immediate loading of threaded implants at stage 1 surgery in edentulous arches: Ten consecutive case reports with 1- to 5-year data. *Int J Oral Maxillofac Implants* 1997;12:319–324.
2. Schnitman PA, Wöhrle PS, Rubenstein JE, DaSilva JD, Wang NH. Ten-year results for Brånemark implants immediately loaded with fixed prostheses at implant placement. *Int J Oral Maxillofac Implants* 1997;12:495–503.
3. Grunder U. Immediate functional loading of immediate implants in edentulous arches: Two-year results. *Int J Periodontics Restorative Dent* 2001;21:545–551.
4. Gapski R, Wang HL, Mascarenhas P, Lang NP. Critical review of immediate implant loading. *Clin Oral Implants Res* 2003;14: 515–527.
5. Wolfinger GJ, Balshi TJ, Rangert B. Immediate functional loading of Brånemark System implants in edentulous mandibles: Clinical report of the results of developmental and simplified protocols. *Int J Oral Maxillofac Implants* 2003;18:250–257.
6. Attard NJ, Zarb GA. Immediate and early implant loading protocols: A literature review of clinical studies. *J Prosthet Dent* 2005;94:242–258.
7. Balshi SF, Wolfinger GJ, Balshi TJ. A prospective study of immediate functional loading, following the teeth in a day protocol: A case series of 55 consecutive edentulous maxillas. *Clin Implant Dent Relat Res* 2005;7:24–31.
8. Bergkvist G, Nilner K, Sahlholm S, Karlsson U, Lindh C. Immediate loading of implants in the edentulous maxilla: Use of an interim fixed prosthesis followed by a permanent fixed prosthesis: A 32-month prospective radiological and clinical study. *Clin Implant Dent Relat Res* 2009;11:1–10.
9. De Bruyn H, Van de Velde T, Collaert B. Immediate functional loading of TiOblast dental implants in full-arch edentulous mandibles: A 3-year prospective study. *Clin Oral Implants Res* 2008;19:717–723.

10. Esposito M, Grusovin MG, Willings M, Coulthard P, Worthington HV. The effectiveness of immediate, early, and conventional loading of dental implants: A Cochrane systematic review of randomized controlled clinical trials. *Int J Oral Maxillofac Implants* 2007;22:893–904.
11. Esposito M, Grusovin MG, Achille H, Coulthard P, Worthington HV. Interventions for replacing missing teeth: Different times for loading dental implants. *Cochrane Database Syst Rev* 2009;21:CD003878.
12. Degidi M, Iezzi G, Perrotti V, Piattelli A. Comparative analysis of immediate functional loading and immediate nonfunctional loading to traditional healing periods: A 5-year follow-up of 550 dental implants. *Clin Implant Dent Relat Res* 2009;11:257–266.
13. Brånemark P-I. Introduction to osseointegration. In: Brånemark P-I, Zarb GA, Albrektsson T (eds). *Tissue-integrated Prostheses: Osseointegration in Clinical Dentistry*. Chicago: Quintessence, 1985:11–76.
14. Reich KM, Frangos JA. Effect of flow on prostaglandin E2 and inositol trisphosphate levels in osteoblasts. *Am J Physiol* 1991;261:C428–C432.
15. Han Y, Cowin SC, Schaffler MB, Weinbaum S. Mechanotransduction and strain amplification in osteocyte cell processes. *Proc Natl Acad Sci (USA)* 2004;101:16689–16694.
16. Kapur S, Baylink DJ, Lau KH. Fluid flow shear stress stimulates human osteoblast proliferation and differentiation through multiple interacting and competing signal transduction pathways. *Bone* 2003;32:241–251.
17. Leucht P, Kim JB, Wazen R, et al. Effect of mechanical stimuli on skeletal regeneration around implants. *Bone* 2007;40:919–930.
18. Guida L, Iezzi G, Annunziata M, et al. Immediate placement and loading of dental implants: A human histologic case report. *J Periodontol* 2008;79:575–581.
19. Kozlovsky A, Tal H, Laufer BZ, et al. Impact of implant overloading on the peri-implant bone in inflamed and non-inflamed peri-implant mucosa. *Clin Oral Implants Res* 2007;18:601–610.
20. Romanos GE, Toh CG, Siar CH, Wicht H, Yacoob H, Nentwig GH. Bone-implant interface around titanium implants under different loading conditions: A histomorphometrical analysis in the *Macaca fascicularis* monkey. *J Periodontol* 2003;74:1483–1490.
21. Schropp L, Wenzel A, Kostopoulos L, Karring T. Bone healing and soft tissue contour changes following single-tooth extraction: A clinical and radiographic 12-month prospective study. *Int J Periodontics Restorative Dent* 2003;23:313–323.
22. Esposito MA, Koukouloupoulou A, Coulthard P, Worthington HV. Interventions for replacing missing teeth: Dental implants in fresh extraction sockets (immediate, immediate-delayed and delayed implants). *Cochrane Database Syst Rev* 2006;18:CD005968.
23. Quirynen M, Van Assche N, Botticelli D, Berglundh T. How does the timing of implant placement to extraction affect outcome? *Int J Oral Maxillofac Implants* 2007;22(suppl):203–223.
24. Crespi R, Capparè P, Gherlone E, Romanos GE. Immediate occlusal loading of implants placed in fresh sockets after tooth extraction. *Int J Oral Maxillofac Implants* 2007;22:955–962.
25. Degidi M, Piattelli A, Carinci F. Immediate loaded dental implants: Comparison between fixtures inserted in postextractive and healed bone sites. *J Craniofac Surg* 2007;18:965–971.
26. Nordin T, Graf J, Frykholm A, Helldén L. Early functional loading of sand-blasted and acid-etched (SLA) Straumann implants following immediate placement in maxillary extraction sockets. Clinical and radiographic result. *Clin Oral Implants Res* 2007;18:441–451.
27. Polizzi G, Grunder U, Goené R, et al. Immediate and delayed implant placement into extraction sockets: A 5-year report. *Clin Implant Dent Relat Res* 2000;2:93–99.
28. Anitua E, Orive G, Aguirre JJ, Andía I. Clinical outcome of immediately loaded dental implants bioactivated with plasma rich in growth factors: A 5-year retrospective study. *J Periodontol* 2008;79:1168–1176.
29. Henry PJ, Liddelou GJ. Immediate loading of dental implants. *Aust Dent J* 2008;53(suppl 1):S69–S81.
30. Adell R, Lekholm U, Brånemark P-I. Surgical procedures. In: Brånemark P-I, Zarb GA, Albrektsson T (eds). *Tissue-integrated Prostheses: Osseointegration in Clinical Dentistry*. Chicago: Quintessence, 1985:211–232.
31. Aires I, Berger J. Immediate placement in extraction sites followed by immediate loading: A pilot study and case presentation. *Implant Dent* 2002;11:87–94.
32. Davarpanah M, Caraman M, Jakubowicz-Kohen B, Kebir-Quelin M, Szmukler-Moncler S. Prosthetic success with a maxillary immediate-loading protocol in the multiple-risk patient. *Int J Periodontics Restorative Dent* 2007;27:161–169.
33. Tarnow DP, Cho SC, Wallace SS. The effect of inter-implant distance on the height of inter-implant bone crest. *J Periodontol* 2000;71:546–549.
34. Ding X, Liao SH, Zhu XH, Zhang XH, Zhang L. Effect of diameter and length on stress distribution of the alveolar crest around immediate loading implants. *Clin Implant Dent Relat Res* 2009;11:279–287.
35. Yoo RH, Chuang SK, Erakat MS, Weed M, Dodson TB. Changes in crestal bone levels for immediately loaded implants. *Int J Oral Maxillofac Implants* 2006;21:253–261.
36. Testori T, Del Fabbro M, Capelli M, Zuffetti F, Francetti L, Weinstein RL. Immediate occlusal loading and tilted implants for the rehabilitation of the atrophic edentulous maxilla: 1-year interim results of a multicenter prospective study. *Clin Oral Implants Res* 2008;19:227–232.
37. Araújo MG, Wennström JL, Lindhe J. Modeling of the buccal and lingual bone walls of fresh extraction sites following implant installation. *Clin Oral Implants Res* 2006;17:606–614.
38. Araújo MG, Sukekava F, Wennström JL, Lindhe J. Tissue modeling following implant placement in fresh extraction sockets. *Clin Oral Implants Res* 2006;17:615–624.