

Case study 42

Immediate Implantation and Immediate Loading of a Full Arch Mandible, Using ICE Implants

Dr. Stuardo Valenzuela Manfredi

About the Author

Dr. Stuardo Valenzuela Manfredi DDS, Bucco-Maxillofacial Implantology Oral Implantology, Prosthodontics & Esthetics Dentistry, Chile



Dr. Manfredi his DMD from Universidad Mayor, Santiago, Chile (2005). In 2011, he completed his specialty in Oromaxillofacial Implantology at the Universidad de Chile (cum laude), and since 2012 he has been a member of the Oral Implantology Society, Chile. In 2015, Dr. Valenzuela received a Diploma in Digital Dentistry, Universidad de los Andes, Chile. He is the Clinical Director of the Alpha-Bio Tec. Chile Training Center, in which he is the leader speaker for introductory courses in surgery and prosthetics. Dr. Valenzuela manages VM Dental Studio, a private practice in Santiago, Chile, dedicated to implantology and aesthetic dentistry. During his career, Dr. Valenzuela has participated in numerous rehabilitation and implant surgery courses and is a frequent guest speaker at industry seminars and conferences worldwide.

Abstract

Full arch immediate loading is a surgical/prosthetic technique well-documented in literature and accepted by patients as treatment time is shorter and patients' comfort improves. In this case, a 52-year-old woman came for a consultation for increased mobility of teeth in the lower jaw. Following physical examination, it was decided to perform the following; extractions of the remaining teeth, immediate installation of 6 ICE Alpha-Bio Tec's implants, guided bone regeneration (GBR) with a bovine xenograft and collagen membrane, and immediate loading with an acrylic screw-retained prosthesis with rigid splinting.

Background

Oral implant-assisted rehabilitation is now a means of treatment widely accepted by both clinicians and patients. Since the first attempt of osseointegration, significant progress has been made in implant macro-design and surface treatments, as well as in treatment time.

Full arch immediate loading with a prosthesis with rigid splinting has become an accepted and evidence-based technique. This type of treatment provides an aesthetic and functional solution for the patients within 48 hours^[1].

Mechanical loads bearing on implants, which induce controlled stress level, have proved to excite osteocytes to produce osteoid matrix, which contributes to better-organized bone around the implant, increases bone-to-implant contact (BIC) and even increases cortical thickness.

The predictability and success of treatment depends both on surgical and prosthetic factors. One of the most important surgical factors is the achievement of suitable primary stability, as well as ensuring proper occlusion for the temporary prosthesis.

One of the primary causes of crest bone loss is occlusal overloading of implant-assisted rehabilitations. Studies of finite models have demonstrated that stress concentrates on the cervical region of the bone crest [2-3].

Quality and quantity have been shown to influence stress concentration around dental implants [3-6].

Low-density cancellous bone increases stress concentration around implants [4-6].

Cortical crest thickness [4] and bone height in relation to implant size can affect stress distribution/contribution. (Meijer et al. 1992; Chun et al. 2002) [7-8].

The first report of an implant in fresh extraction sockets was published in 1976; in 1989, Lazzara concluded that implants in fresh extraction sockets helped to prevent bone reabsorption that takes place after extraction [9].

More recent studies have demonstrated that the insertion of just one implant in an alveolus post-extraction does not prevent bone loss. Such bone loss in both vestibular bone and bone height can cause the aesthetic failure of assisted implant rehabilitation, since it can give rise to the following:

- Soft tissue recession
- Exposure of implant threads
- Absence of papilla
- Visualization of a grey tone in the vestibular gum above the implant.

The most serious of these complications is soft tissue recession, which may occur due to the following factors [10]:

- Thin periodontal biotype
- Vestibular position of the implant
- Extremely thin or absent of vestibular plate [11].

The ideal 3D positioning of the implant, in a post-extraction alveolus, can be complicated due to the anatomy of the alveolus, its position, or the number of roots in the tooth.

Primary stability is a determining factor in the result of post-extraction implants, as well as other factors that determine changes in bone tissue around post-extraction implants, which are as follows:

- Immediate loading or delayed-loading
- Number of remaining alveolar walls
- Size of gap between implant and buccal plate
- Necessity of bone grafting
- Platform switching

Surgical technique in post-extraction implants in order to attain an ideal 3D position is based on drilling at the expense of the palatal wall and the apical sector of the alveolar bone. Due to this, the bone resource on which the implant is stabilized is smaller than on the healed ridges. In view of this, the drilling sequence, but above all, the macro-design of the implant to be used is of great importance in post-extraction alveoli [11-14]. The macro-design of the implants to be used must have the following characteristics to attain primary stability compatible with immediate implantation and loading:

- Tapered body and core
- Variable threads design
- Wide thread pitch
- Self-drilling
- Self-condensing

Immediate implantation and immediate loading of a full arch mandible, using ICE implants

Case Overview

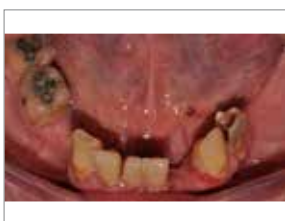A 52-year-old patient with no important systemic pathologies, non-smoker, complained of increased mobility of the remaining teeth in the lower jaw due to severe bone reabsorption of the bone support resource. During the extra-oral examination, no important abnormalities were detected. In the intraoral examination, no active infections were found. The X-ray check showed adequate bone resource for performing the installation of implants in fresh extraction sockets.

Materials Used

2 ICE implants Ø4.65 x L 10 mm
4 ICE implants Ø3.75 x L 11.5 mm
6 TCT - N abutments
6 SF - N, screw fixation, as a healing cap for TCT - N
6 HCTB - N,
6 TTA - N temporary abutment for TCT - N
6 SF - N, screw fixation for TCT - N.
6 PST - N, Non Engaging, as final abutment
6 BTT - N, Analogs
6 TST - N, and 6 SFL - N, as open tray transfer
Bovine xenograft
Collagen membrane

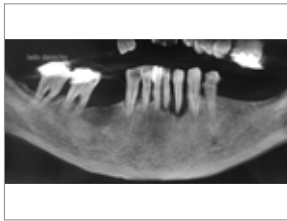
Treatment Plan

Due to the clinical condition of the remaining teeth, it was decided to extract them in the same surgery. In view of the current bone resource, placement of 6 ICE AlphaBio Tec. implants was performed, as well as the filling of the gap with a bovine xenograft. Fenestrations were also treated with a bovine xenograft, plus a collagen membrane. Immediately after surgery, an impression was taken with a multifunctional tray so that the immediate loading of implants should be affected by means of an acrylic prosthesis with rigid splinting installed 48 hours post-surgery. Three months after the surgery, a permanent prosthesis was installed.

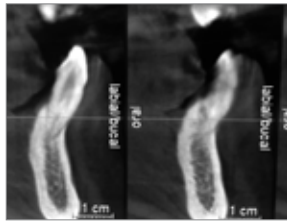


1 Pre-surgical view

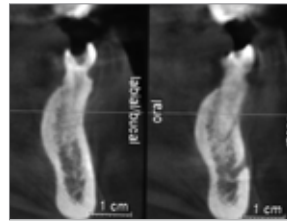
Pre-surgical CBCT (2a - 2j)



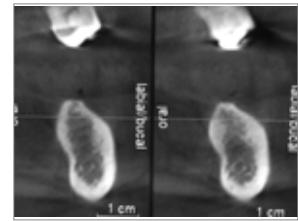
2a



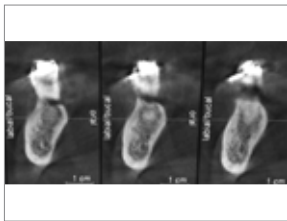
2b



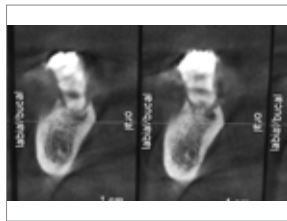
2c



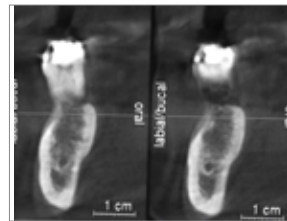
2d



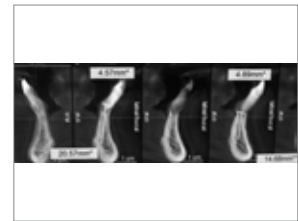
2e



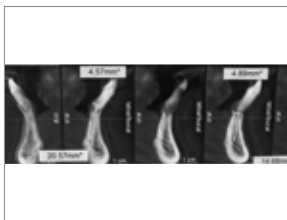
2f



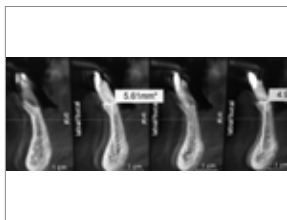
2g



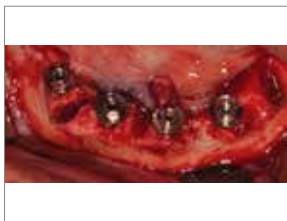2h



2i



2j

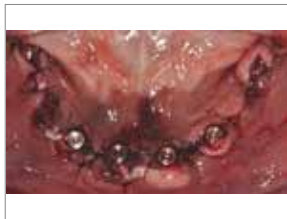

3 Examination of implants and installation of TCT-N

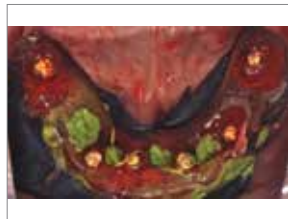Immediate implantation and immediate loading of a full arch mandible, using ICE implants



4 Guided bone regeneration with bovine xenograft and slow-resorbing collagen membrane, and installation of HCTB-N abutment as protection of TCT-N abutment.



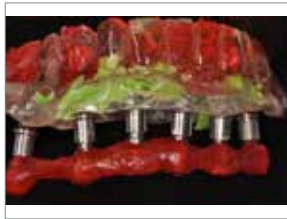5 Post-surgical view, viewing of HCTB-N abutments.



6 Impression for immediate loading performed immediately after surgery, with multifunctional tray.



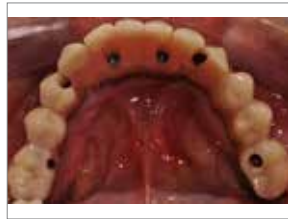7 Impression with multifunctional tray



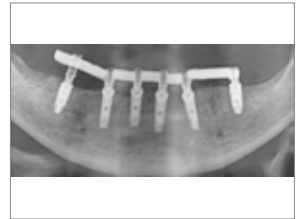8 Impression view multifunctional tray and drilling of BTT-N analogs



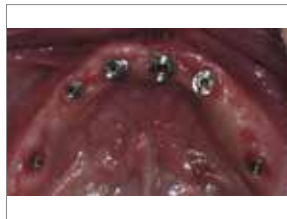9 Temporary acrylic screw-retained prosthesis with rigid splinting.



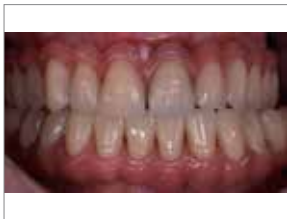10 Immediate loading, installed in mouth 48 hours post-surgery.



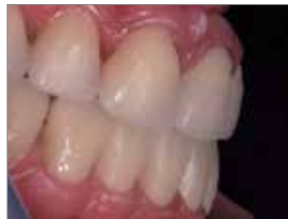11 Panoramic X-ray, 15 days post-surgery.



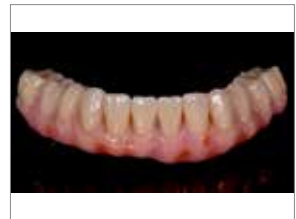12 Occlusal view, three months post-surgery.



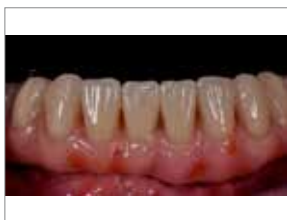13 Aesthetic test in wax



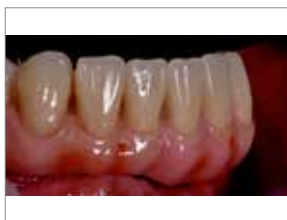
14 Aesthetic test in wax, side view



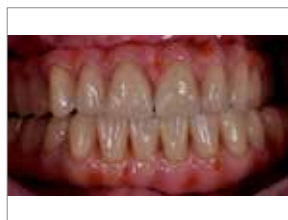15 Completed acrylic prosthesis



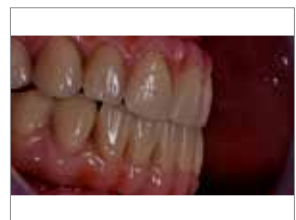16 Screwed retained metal acrylic prosthesis, front view



17 Side View



19 Final Front View



19 Final Side View

Conclusions

In this clinical case, an immediate implantation of 6 ICE implants and full arch immediate loading in was described. Essential in these procedures was high primary stability, achieved by the use of ICE implants, providing an esthetically effective method of rehabilitation in a short time period.

Bibliography

1. Ferrus J, Cecchinato D, Pjetursson EB, Lang NP, Sanz M, Lindhe J. Factors influencing ridge alterations following immediate implant placement into extraction sockets. *Clin. Oral Impl. Res.* 29–22 ;2010 ,21.
2. Van Oosterwyck H, Duyck J, Vander Sloten J, Van der Perre G, De Cooman M, Lievens S, Puers R, Naert I. The influence of bone mechanical properties and implant fixation upon bone loading around oral implants. *Clin Oral Implants Res.* 1998 Dec;18-407:(6)9
3. O'Mahony AM, Williams JL, Spencer P. Anisotropic elasticity of cortical and cancellous bone in the posterior mandible increases peri-implant stress and strain under oblique loading. *Clin Oral Implants Res.* 2001 Dec;57-648:(6)12
4. Holmes DC, Loftus JT. Influence of bone quality on stress distribution for endosseous implants. *J Oral Implantol.* 1997;23(3):104-11.
5. Martinez H, Davarpanah M, Missika P, Celletti R, Lazzara R. Optimal implant stabilization in low density bone. *Clin Oral Implants Res.* 2001 Oct;32-423:(5)12.
6. Tada S., Stegaroiu R., Kitamura E, Miyakawa O, Kusakari H. Influence of implant design and bone quality on stress/strain distribution in bone around implants: a 3-dimensional finite element analysis. *Int J Oral Maxillofac Implants.* 2003 May-Jun;18(3):357-68
7. Meijer HJ, Starmans FJ, Steen WH, Bosman F. A three-dimensional, finite-element analysis of bone around dental implants in an edentulous human mandible. *Arch Oral Biol.* 1993 Jun;6-491:(6)38.
8. Chun HJ, Cheong SY, Han JH, Heo SJ, Chung JP, Rhyu IC, Choi YC, Baik HK, Ku Y, Kim MH. Evaluation of design parameters of osseointegrated dental implants using finite element analysis. *J Oral Rehabil.* 2002 Jun;74-565:(6)29.
9. Lazzara RJ. Immediate implant placement into extraction sites: surgical and restorative advantages. *Int J Periodontics Restorative Dent.* 1989;9(5):332-43.
10. Frank Peter Strietzel, Adi Lorean, Implant-Prosthetic Rehabilitation of the edentulous maxilla and mandible with immediate loaded implants: Preliminary data from retrospective study, considering time of implantation, *Int J Oral Maxillofac Implants,* 147-26:139;2011
11. Araujo M.G., Sukekava F., Wennström J.L. & Lindhe J. Tissue modeling following implant placement in fresh extraction sockets. *Clinical Oral Implants Research* 624–615 :17 2006.
12. Araujo M.G. & Lindhe J. Dimensional ridge alterations following tooth extraction. An experimental study in the dog. *Journal of Clinical Periodontology* 218–212 :32 2005.
13. Araujo M.G., Sukekava F., Wennström J.L. & Lindhe J. Ridge alterations following implant placement in fresh extraction sockets. An experimental study in the dog. *Journal of Clinical Periodontology* 652–645 :32 2005.
14. Araujo MG, Linder E, Lindhe J. Bio-Oss in the buccal gap at immediate implants: a -6month study in the dog *Clin. Oral Impl. Res.* 8–1 ;2011 ,22.



Alpha-Bio Tec Ltd.

7 Hatnufa St., P.O.B. 3936. Kiryat Arye,
Petach Tikva 4951025, Israel
T. +972.3.9291000
F. +972.3.9235055
sales@alpha-bio.net

MEDES LIMITED

5 Beaumont Gate, Shenley Hill
Radlett, Herts WD7 7AR. England
T./F. +44.192.3859810

International

T. +972.3.9291055
F. +972.3.9291010
export@alpha-bio.net

www.alpha-bio.net