



Immediate Implantation Using Alpha-Bio Tec's NeO Implant



Dr. Albert Franck Zerah
DMD, France

Dr. Albert Franck Zerah graduated from the Faculty of Dental Surgery, in 1987. Dr. Zerah served as clinic head of the Stomatology and Maxillofacial Department, Broussais Hospital, Paris and head of the Department of Oral Surgery (Oral and Maxillofacial Reconstruction and Implantology), Clinique de la Dhuys, Bagnolet (France), from 1992-1995. He continued his post-graduate studies in dental surgery, periodontology and implantology at New York University until 1999, followed by post-graduate studies in orthodontics at Bordeaux University until 2001. Since 2001, Dr. Zerah has held the position of Head of the Oral Surgery Department (Oral and Maxillofacial Reconstruction and Implantology),

Clinique Victor Hugo, Paris. He serves as a training cycle director for various implant manufacturers and as a research director, focusing on the development of new implants. Dr. Zerah is the Chairman of SPIOA (Parisian Society of Implantology and Orthodontics); Research Director, with a focus on piezosurgery, for the EMS Society; Director of piezosurgery training for the Mectron society, and Research Director, focusing on OP 300 (orthopantomograph technology for dental imaging) for the Instrumentarium Society.

Immediate Implantation Using Alpha-Bio Tec's NeO Implant

Abstract

For several years, it was generally accepted that placement of an implant should be deferred, often for several months, following a root extraction. In the 1970s, analysis of bone remodeling mechanisms showed that bone resorption made implant placement difficult, with results that were less than cosmetically optimal in most cases. For this reason, implant specialists began to consider placing implants directly following an extraction, to counteract the adverse effects of bone resorption, treating the implant like a “metal beam” to support and stabilize bone volume. Since the 2000s, immediate implantation has become established practice whenever the environmental context is suitable. This case study will use three clinical cases to illustrate the rules and protocols for implant crowns, in order to achieve good aesthetic and functional outcomes in a predictable way.

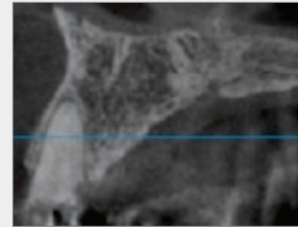
Background

Basic Rules

Immediate implantation should be done whenever possible. However, as stated above, several rules must be complied with. Failure to do so will lead to almost certain, and oftentimes resounding failure, as the post-surgery clinical state will be more difficult to manage in other respects (significant bone loss, unsightly gingival recession, and often damage to adjacent teeth).

What are the rules to follow when planning an immediate implantation?

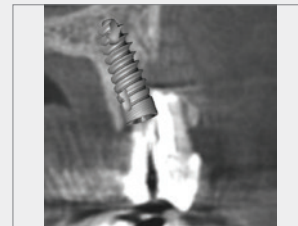- 1 First, the post-extraction residual bone volume must be analyzed. Following the extraction, the vestibular bone wall must be intact (**Fig. 1**), and of at least a minimum thickness.



1

Checking bone wall thickness

The extraction must be done in a completely non-traumatic way, preserving the residual alveolar ridges as much as possible. (A surgical bur can be used to cut the remaining root, and the root can be extracted in several pieces without prying open the residual bone, thereby preserving its integrity). An extremely thorough debridement of the alveolus must be carried out to eliminate any residue of inflammatory or infectious tissue. If part of the vestibular bone wall was destroyed and fenestration is present, a sufficient vestibular bone must remain in place and bone graft filling should be added, in order to achieve high primary stability. (**Fig. 2**)



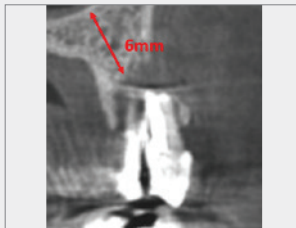
2

Implant with graft in an alveolus, with fenestration

In addition, it is important to assess the width of the alveolus with respect to the diameter of the implant that is to be placed.

There are two possible configurations:

If the width of the alveolus is greater than the diameter of the implant, primary stability is possible. If the width of the alveolus is less than the diameter of the implant, a minimum 3 mm of “implantable” bone beyond the alveolus must be confirmed in order to achieve primary stability in the implanted bone. **(Fig. 3)**



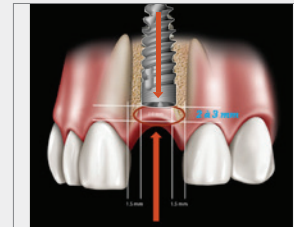
3

Measurement of residual bone beneath the alveolus

Moreover, to avoid resorption of the wall around the proposed implant, it is essential that the remaining wall has a thickness of at least 1 mm. Stress on the bone when it is compressed by the implant placement leads to systematic bone loss in the remaining wall, and thus, failure from an aesthetic standpoint (grayish gingival border).

The analysis of the residual bone volume must also follow two basic rules:

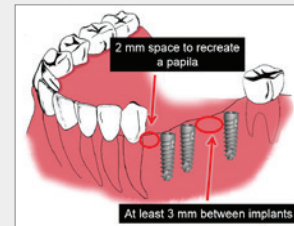
- a) The implant abutment must never be situated more than 3 mm below the enamel-cementum junction of the adjacent teeth. **(Fig. 4)**



4

Positioning of the implant on the alveolar ridge

- b) The implant must be placed at a maximum of between 1.5 and 2 mm from an adjacent tooth (basic rule for regrowth of the interdental papillae), and the distance between two implants must be between 2.5 and 3 mm. **(Fig. 5)**



5

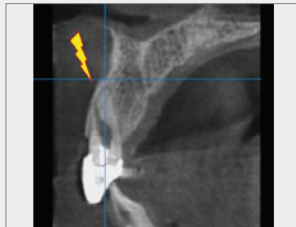Distance between two implants and to one adjacent tooth

- ② Second, the gingiva must be analyzed, not only around the remaining root, but also around the adjacent teeth. Mucous membranes must show adequate volume, no inflammation, and a height that is conducive to healthy peripheral regeneration, with the subsequent creation of new papillae. An absence of attached gingiva is not a formal counterindication for immediate implant, but does require that a graft be considered, whether in the form of a buried connective tissue graft or a free gingival graft, in order to protect the implant and any bone graft that is done.

Basic Protocols

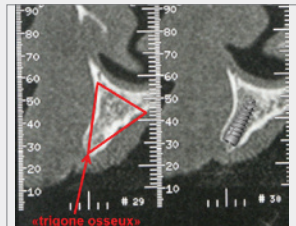
Basic protocols also govern immediate implantation in the aesthetic area. These protocols are implemented for implants in anterior quadrants, whether upper or lower. The greatest challenge is, of course, management of the antero-superior area. Here, the orientation and thinness of the cortical tissue, the soft tissue thickness, the problem of papillae and crowns, and management of aesthetic outcomes of the crown on the implant, all represent challenges that are sometimes very difficult to surmount.

It must be kept in mind that the alveolar axis is usually very close—even too close—to the vestibular cortex. Following the alveolar axis in the placement of the implant, in the majority of cases, puts stress on this cortical tissue, and may even cause perforation of the vestibular bone, inevitably leading to bone loss in this area. **(Fig. 6)**



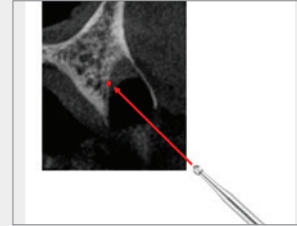
6
Alveolar axis

This is why drilling must be done inside the “triangle of bone,” or as close to the palatal bone as possible. **(Fig. 7)**



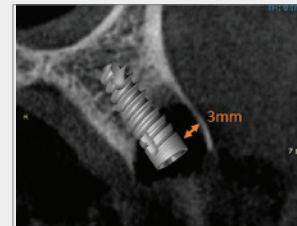
6
Triangle of bone

To do this, a surgical ball bur is used to mark the bone at the center of the alveolus toward the palatal bone, and care is taken to follow the axis created by this ball bur, in order to avoid the alveolar axis. **(Fig. 8)**



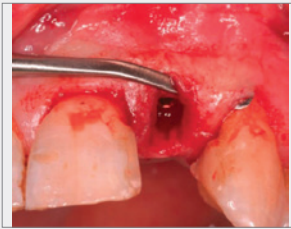
8
Positioning of the marking ball bur

The other important step is to fill the gap between the diameter of the implant and that of the alveolus. This filling must be done consistently whenever there is a gap greater than 1 mm. **(Fig. 9)** It must also be covered with a separating membrane to keep the mucus membrane fibroblasts from touching the bone graft.



9
Distance between the alveolus and the implant diameter

When dealing with the soft tissue aspect of this problem, in order to avoid any gingival recession, the gingiva must be incised on the crestal portion and simply separated from the bone, with insertion of a membrane, all the while verifying that no external lesions of the residual bone are present (perforations or significant fractures). **(Fig. 10)**



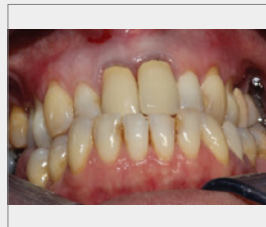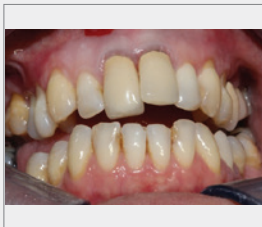10 Removal without incision

Lastly, a gingival graft must be placed on the site, perioperatively or postoperatively, whenever there is a deficiency of mucous membrane that jeopardizes the health of the biological space around the implant.

Clinical Cases

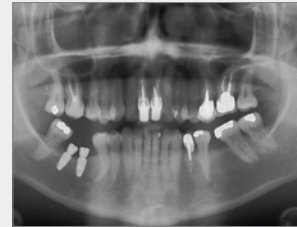
The three clinical cases presented here are characteristic of three different indications: with or without bone filling, with or without a membrane, with temporary fixed denture prosthesis, removable denture prosthesis, or without transitional prosthesis.

Case I: Female patient, age 35, presented with lesions in her two central upper incisors: an internal crack in the central upper left incisor, which was caused by placement of an excessively long root post, and a fracture-type lesion on the central upper right incisor due to poor positioning of the root post (post outside of the pulp canal axis). (**Fig. 11**)

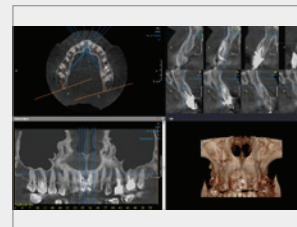


11 Open mouth, closed mouth

As this patient felt pain every time she closed her mouth, an immediate implantation at the two sites was decided upon after analysis of the surrounding bone and mucous tissue. A radiological assessment was done using panoramic and cone-beam imaging. (**Fig. 12, 13**)

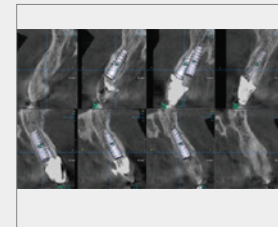
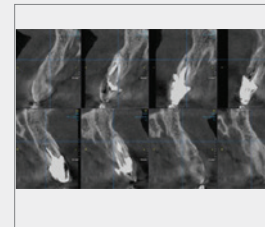


12 Panoramic radiography



13 Cone-beam radiography

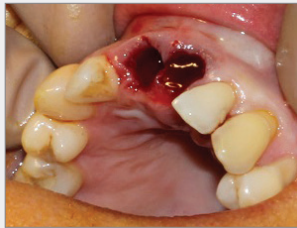A pre-implant simulation was done to visualize the positioning of the planned implants. (**Fig. 14**)



14 Implant simulation

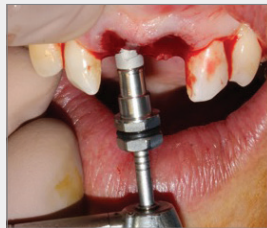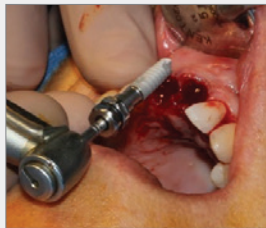This case was a particular challenge due to the patient's Class 3 malocclusion. Were the incisors were to be repositioned in the normal line of occlusion, it would be physically impossible for the patient to close her mouth (lack of inter-occlusal space).

A transitional removable prosthesis, made entirely of acrylic, was therefore decided upon. The incisors would be repositioned in front of the lower incisors, using this opportunity to simultaneously resolve the aesthetic problem. The extractions were therefore done in a non-traumatic manner by severing the roots, as stated above, in order to preserve the vestibular cortices. **(Fig. 15)**



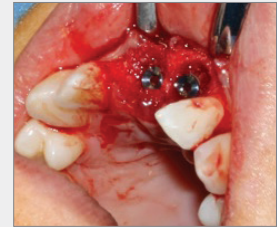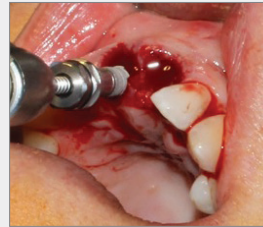
15
Extractions

After having marked the bone at the midpoint of the alveolus, and after preparing the implant shafts, two Ø4.2X13 mm NeO implants were placed. **(Fig. 16)**



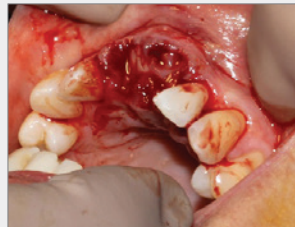
16 Placement of NeO implants

As the space between the implants and the margin of the alveoli was greater than 1 mm, the space was filled with bone drill debris aspirated using a surgical aspirator fitted with a filter. **(Fig. 17)**



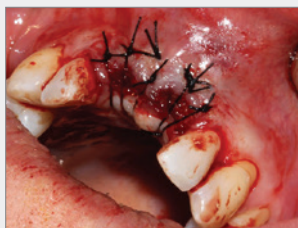17 Filling of the space between the implant and the alveolus

Once the filling was completed, the sites were covered with fibrin (PRF) membranes obtained from a centrifuged sample of the patient's blood. **(Fig. 18)**



18
Protection of the site using PRF

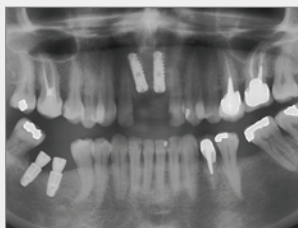
The gingival tissues were then mobilized by periosteum scarification and sutured with two "far-far near-near" sutures, resembling mattress stitches, which allow purse-string sutures to be achieved. This method eliminates tension where the gingival flaps come together, which is often the reason that the surgical site opens up, endangering the graft and the implants. **(Fig. 19)** This was followed by simple interrupted suturing.



19

Sutures

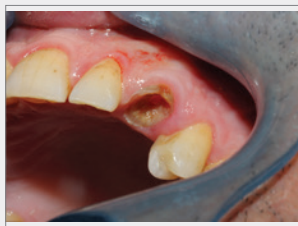The entire site was then covered by a transitional prosthesis adapted so that it did not compress the surgical site, but rather protected it. Panoramic imaging was done, showing good primary stability of the implants. **(Fig. 20)**



20

Post-operative radiology

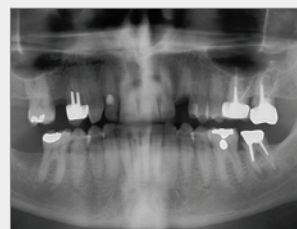
Case II: Male patient, age 55, presented with a canine tooth of which only the root portion remained. The patient had lost the crown of this tooth a long time ago, and it was confirmed by x-ray that this root was completely unrecoverable as the decay was too extensive. **(Fig. 21)**



21

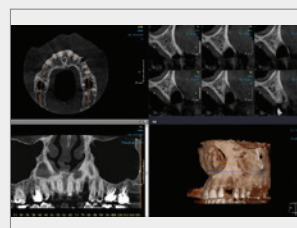
Initial state

A radiological assessment was carried out using panoramic and cone-beam imaging, which also showed agenesis of the 2nd maxillary right premolar. **(Fig. 22, 23)**



22

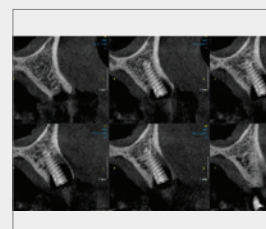
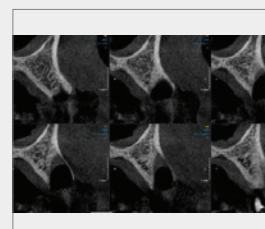
Panoramic radiography



23

Cone-beam radiography

Two implants were therefore planned to replace these two teeth. **(Fig. 24)**

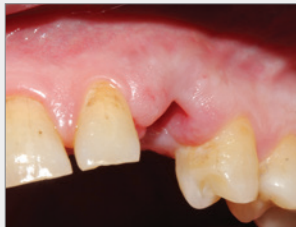

24

Implant simulation

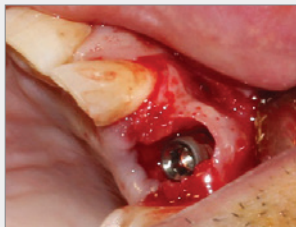Temporary fixed or removable prostheses were also recommended to the patient, but because he had been living with the problem for a long time, and was not uncomfortable with this clinical condition, he had no problem staying that way.

Non-traumatic extraction of the canine was done, but in this specific case it was decided to defer placement of the implant by four days, since the root had been exposed for too long and there was the possibility of a bacterial infection of the area. **(Fig. 25)** Antibiotic therapy was initiated immediately after the extraction, and four days later, the implants were placed.



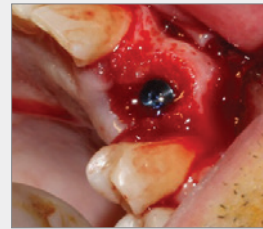25
Site post-extraction

The first implant was placed in the premolar site, because bone drill debris could be recovered by means of the bone filter, as in the surgery above. The canine implant was then prepared, where a Ø4.2X13 mm NeO implant was placed. In this particular case, it was confirmed that there was considerable room between the residual bone and the implant, which was located very close to the palatal bone (a positioning due to the fact that the vestibular wall was thin and therefore fragile). **(Fig. 26)**

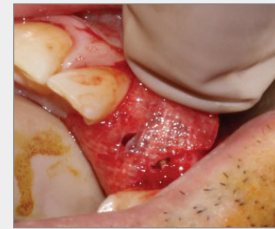

26
NeO implant in place

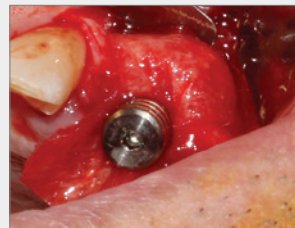
Autogenous bone was then used to fill this space and, given the importance of the space, it was decided to cover it with a resorbable membrane for 4 months. **(Fig. 27)**



27 Fill graft and placement of the membrane

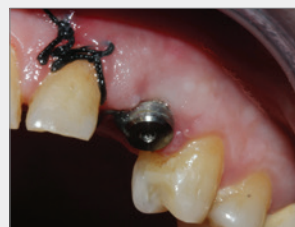

Normally, this membrane is stabilized using tacks, but in this case, because the patient did not wish to have a temporary prosthesis, the membrane was fixed with a healing abutment. To accomplish this, a hole was made in the membrane and the abutment and the membrane were put in place at the same time. **(Fig. 28)**



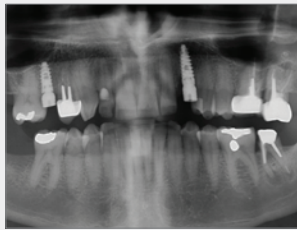
28
Stabilization of the membrane with the healing abutment

Simple interrupted suturing was then done. **(Fig. 29)**



29
Sutures

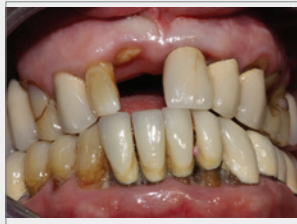A radiological examination was done showing that every thing was sealed. **(Fig. 30)**



30

Panoramic radiography examination

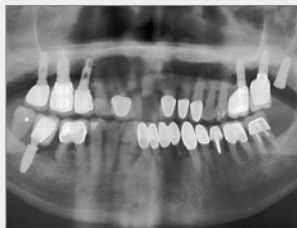Case III: Male patient, age 67, victim of a bicycle accident. **(Fig. 31)**



31

Initial state after the accident

Panoramic imaging was done on this patient in the emergency room, who presented with a crown fracture of the central upper right incisor, a fracture of the enamel of the central upper left incisor, and extreme mobility of the implant located in the second upper right premolar. **(Fig. 32)**

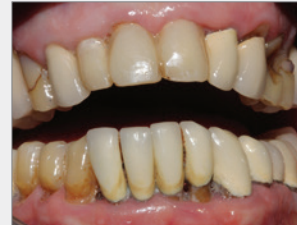

32

Post-trauma panoramic radiography

Because of the patient's psychological fragility, the trauma of the accident, and the patient's concern over his appearance,

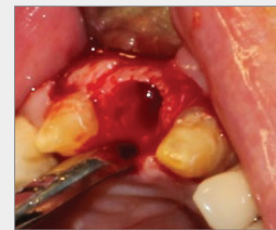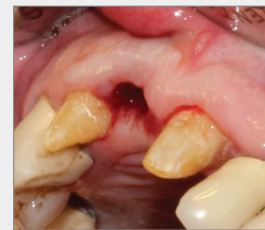a temporary bridge was chosen to replace the fractured central incisor, using the two adjacent teeth as support without extracting the fractured root (after coating the fractured ceramic crown and trimming the fractured lateral incisor). **(Fig. 33)**



33

Temporary bridge from teeth 12 to 21

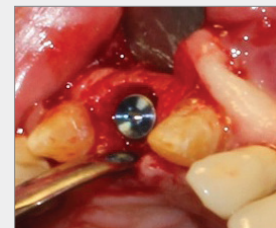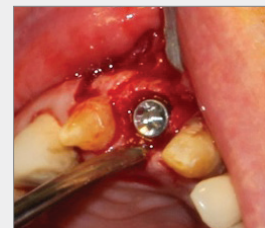Then the root was extracted, non-traumatically as before. **(Fig. 34)**



34

Extraction of the central incisor

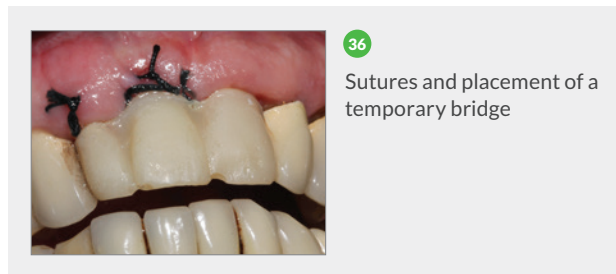
Following the same protocol as the previous cases, a Ø4.2X13 mm NeO implant was placed as close to the palate as possible. **(Fig. 35)**



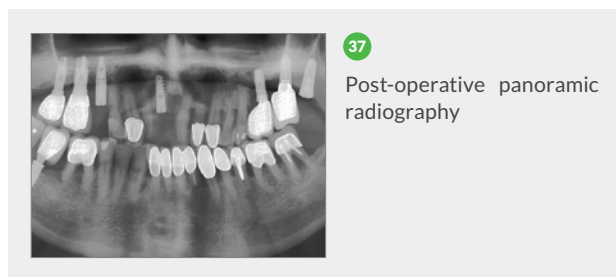
35

Placement of the NeO implant

In this case, it was decided that since the space between the implant and the alveolus was less than 1 mm, the space would not be filled. The gingival flaps on the vestibular and palatal sides were then separated so that they would have a certain laxity and be able to cover the surgical site without too much tension. A “far-far near-near” suture was done, followed by simple interrupted sutures. **(Fig. 36)**



Radiological imaging was then done, confirming the good positioning of the implant. **(Fig. 37)**



Conclusion

As noted above, whenever the criteria are met, the best solution appears to be immediate implantation. This surgical intervention can ensure good stability, thus guaranteeing that the tissues surrounding the implant will be in good condition. It is essential, however, to fully analyze the case, and in the majority of cases to prepare a transitional post-surgical prosthesis, whether fixed or removable. If immediate occlusal loading is to be used, occlusal analysis

of the patient and measurement of the interdental space must be carried out with precision. One must therefore “work backwards,” starting with the prosthesis before proceeding to the surgery, as nothing is more damaging to one’s credibility than a patient leaving without his or her teeth, especially if these were initially promised.

References

1. Champagnat J. F., L'implantologie immédiate : indications, contre-indications, méthodes chirurgicales [Immediate implantation: indications, counter-indications, surgical methods]. *L'inf. Dent*, 1993; 34:2551-2560.
2. Chen S.T., Wilson Jr T.G., Hämmerle C.H.F., Immediate or early placements of implants following tooth extraction: review of biologic basis, clinical procedures and outcomes. *Int J Oral Maxillofac Impl*, 2004; 19: 12-25.
3. Wilson Jr T.G., Schenk R., Buser D., Cochran D., Implants placed in immediate extraction sites: a report of histologic and histometric analysis of human biopsies. *Int J Oral Maxillofac Implants*, 1998; 13(3): 333- 341.
4. Martinez H, Davarpanah M., Préservation de l'architecture dento-alvéolo-gingivale [Preservation of dental-alveolar-gingival architecture]. *Inform Dent*, 2003; 24: 1675-1679.
5. Dohan S., Choukroun J., Dohan A., Donsimoni J. M., Gabrieleff D., Fioretti F., Dohan D., Platelet Rich Fibrin (PRF) : un nouveau biomatériau de cicatrisation. [PRF: a new cicatrizing biomaterial]. *Implanto*, April-June 2004; vol 13, No. 2: 87-115.
6. Hämmerle C.H.F., Chen S.T., Wilson Jr T.G., Consensus statements and recommended clinical procedures regarding the placement of implants in extraction sockets. *Int J Oral Maxillofac Implants*, 2004; 19: 12-25.
7. Esposito M., Grusovin M.G., Willings M., Coulthard P., Worthington H.V., Interventions for replacing missing teeth: different times for loading dental implants. *Cochrane database Syst Rev*, 2007; April 18(2): CD003878.

8. Misch C.E., Density of bone: effect on treatment plans, surgical approach, healing and progressive bone loading. *Int J Oral implantol*, 1990; 6(2): 23-31.
9. Oesterle L.J., Cronin R.J. Jr, Ranley D.M., Maxillary implants and the growing patient. *Int J Oral Maxillofac Implants*, 1993; 8: 377-387.
10. Missika P., Implantation immediate ou différée: le moment fait-il la différence? [Immediate or deferred implantation? Does the time of intervention make a difference?] *Implant, Hors-série [special edition] no. 4. Cahiers de prothèse*, October 1994; 4:84-86.